Ministério da Educação
Universidade Federal do Triângulo Mineiro, Uberaba, MG
Disciplina de Patologia Geral

Nefropatia Diabética

Marlene Antônia dos Reis
mareispatologia@gmail.br

Diabetes Mellitus

Tipo I – dependente de Insulina

Tipo II – não dependente de Insulina

Hiperglicemia

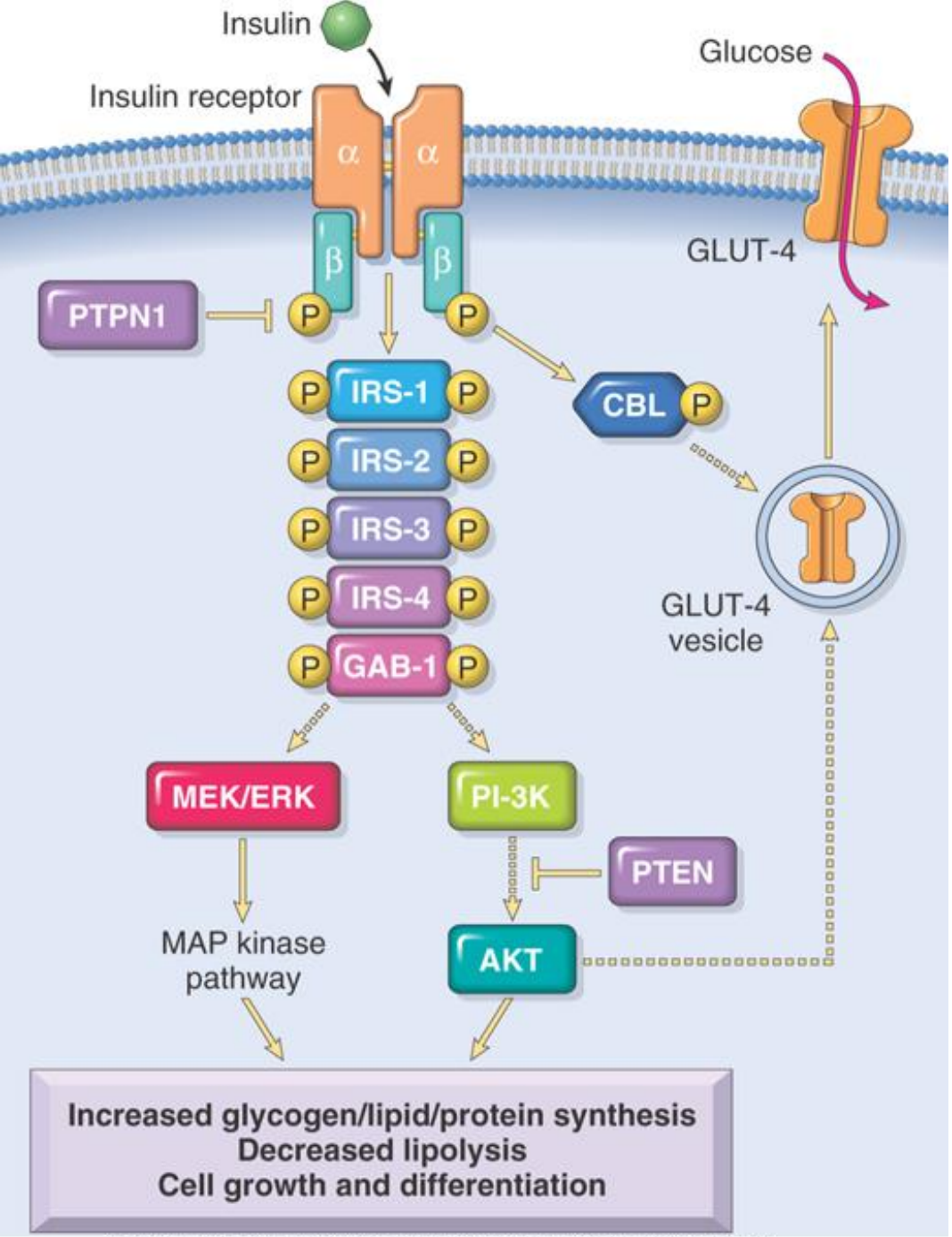

Kumar et al: Robbins & Cotran Pathologic Basis of Disease, 8th Edition.
Copyright © 2009 by Saunders, an imprint of Elsevier, Inc. All rights reserved.

Glicose

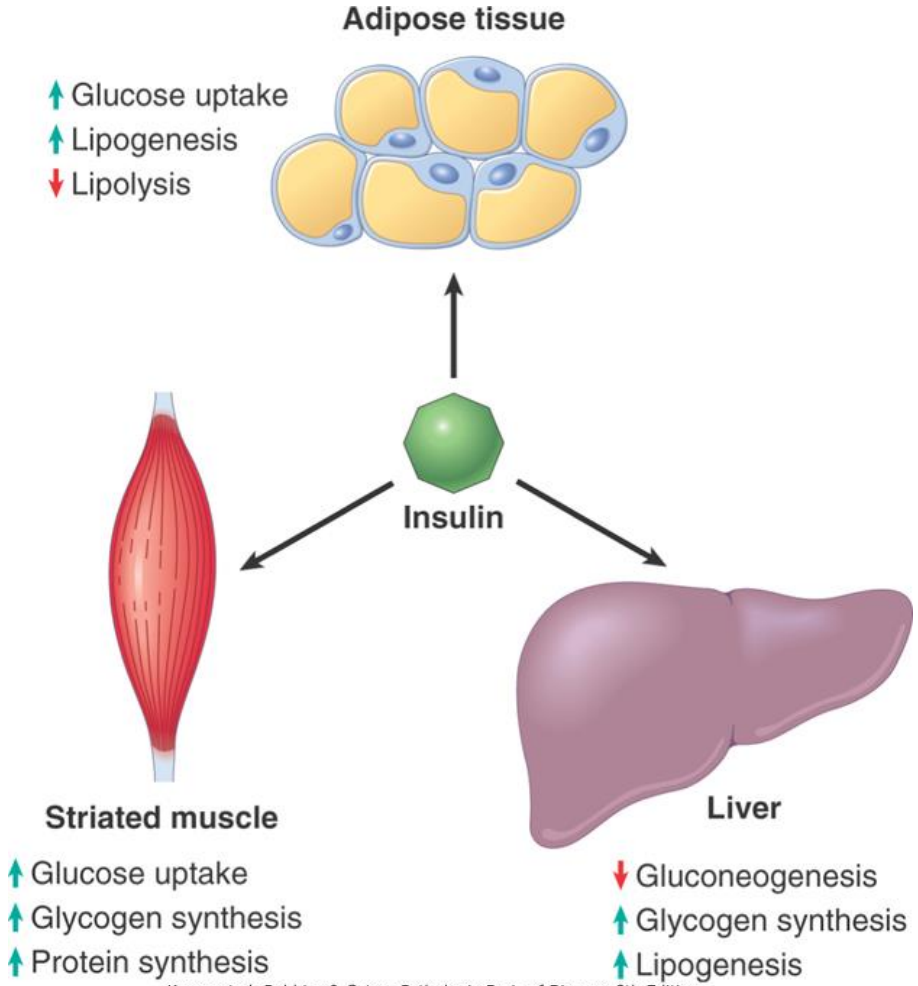

Kumar et al: Robbins & Cotran Pathologic Basis of Disease, 8th Edition.
Copyright © 2009 by Saunders, an imprint of Elsevier, Inc. All rights reserved.

Rim, vaso e tecido nervoso
Não depende da insulina

Diabetes *Mellitus*
Hiperglicemia

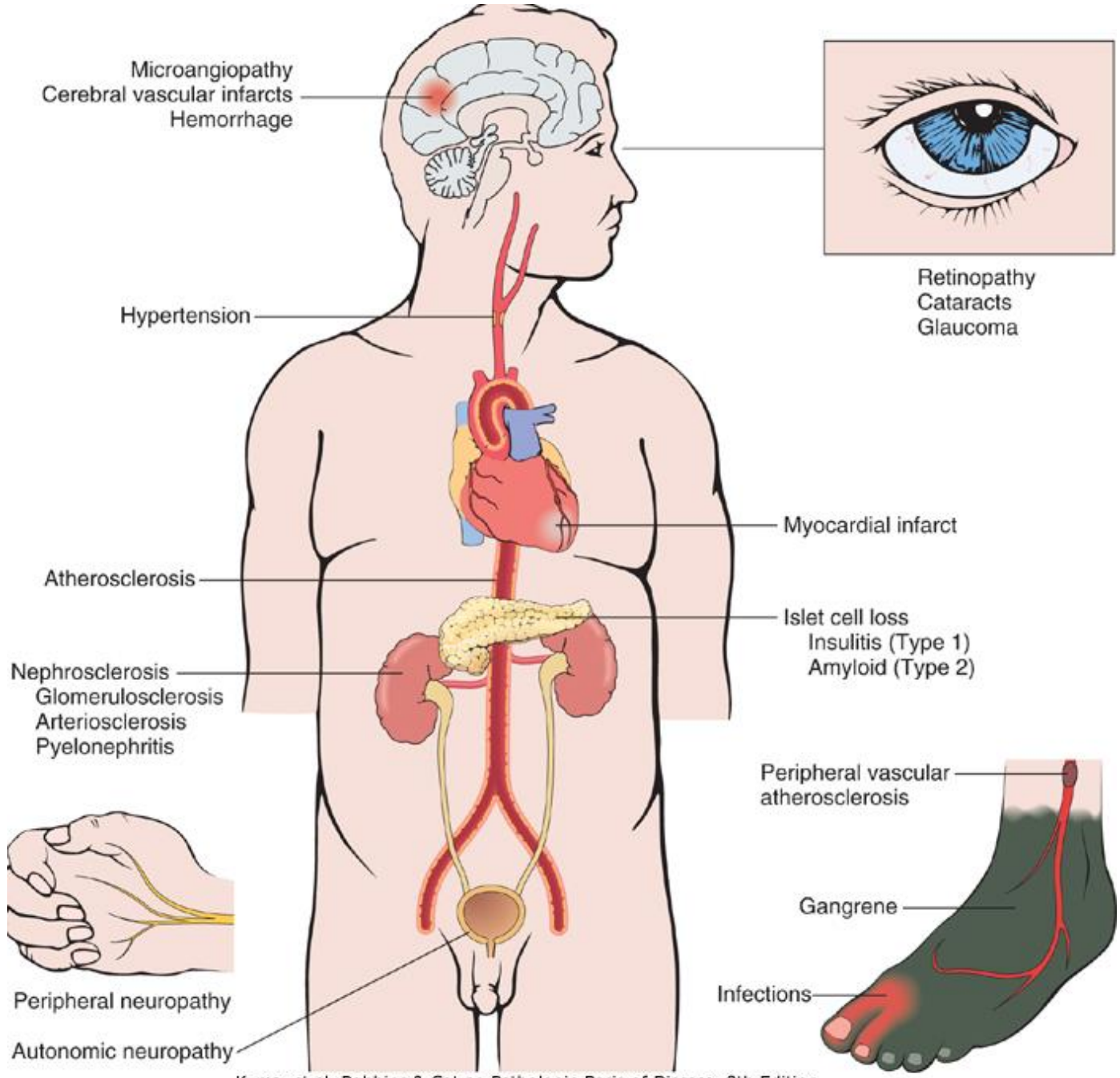

Kumar et al: Robbins & Cotran Pathologic Basis of Disease, 8th Edition.
Copyright © 2009 by Saunders, an imprint of Elsevier, Inc. All rights reserved.

Vaculopatia

Hialinose arteríola

Hialinose arteríola

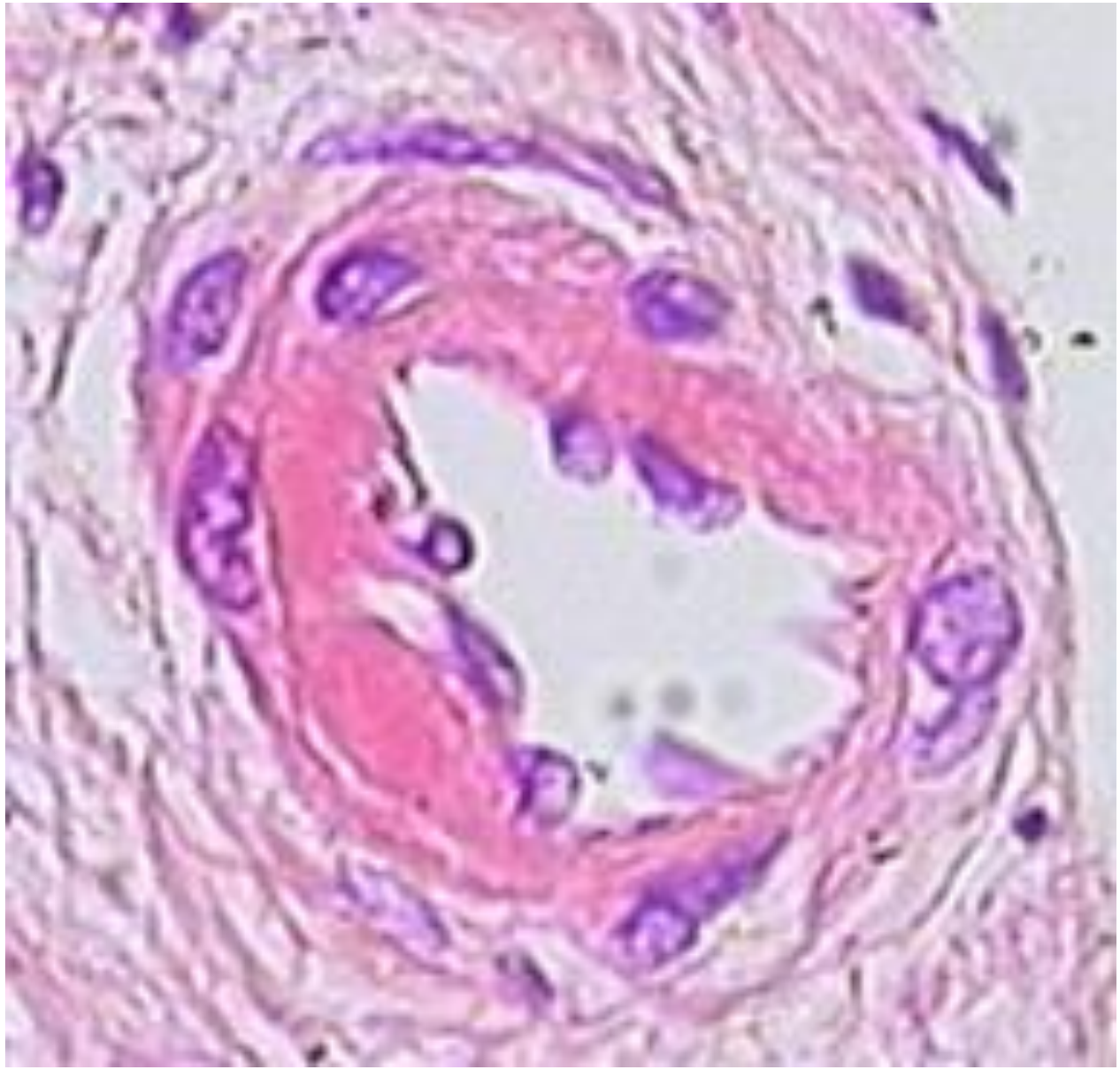

Retinopatia Diabética

http://health.indiamart.com/eye-care/hypertension-and-eye.html

estreitamento, vasoespasmo
microinfartos = manchas algodonosas
hemorragia
edema de papila

Diabetes *Mellitus*
Hiperglicemia

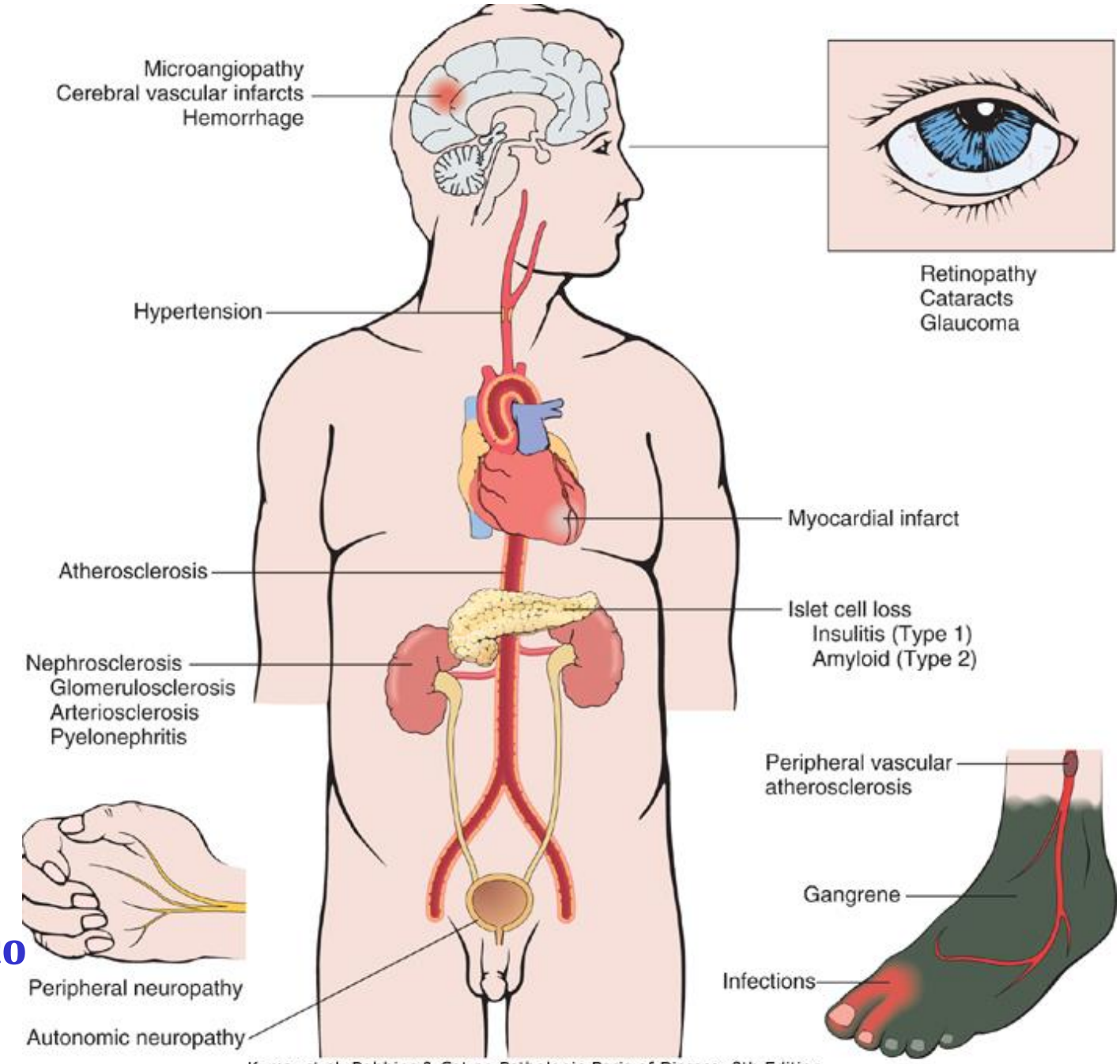

Kumar et al: Robbins & Cotran Pathologic Basis of Disease, 8th Edition.
Copyright © 2009 by Saunders, an imprint of Elsevier, Inc. All rights reserved.

Vaculopatia

Hialinose arteríola

Espes. Fibroelástico

Artéria

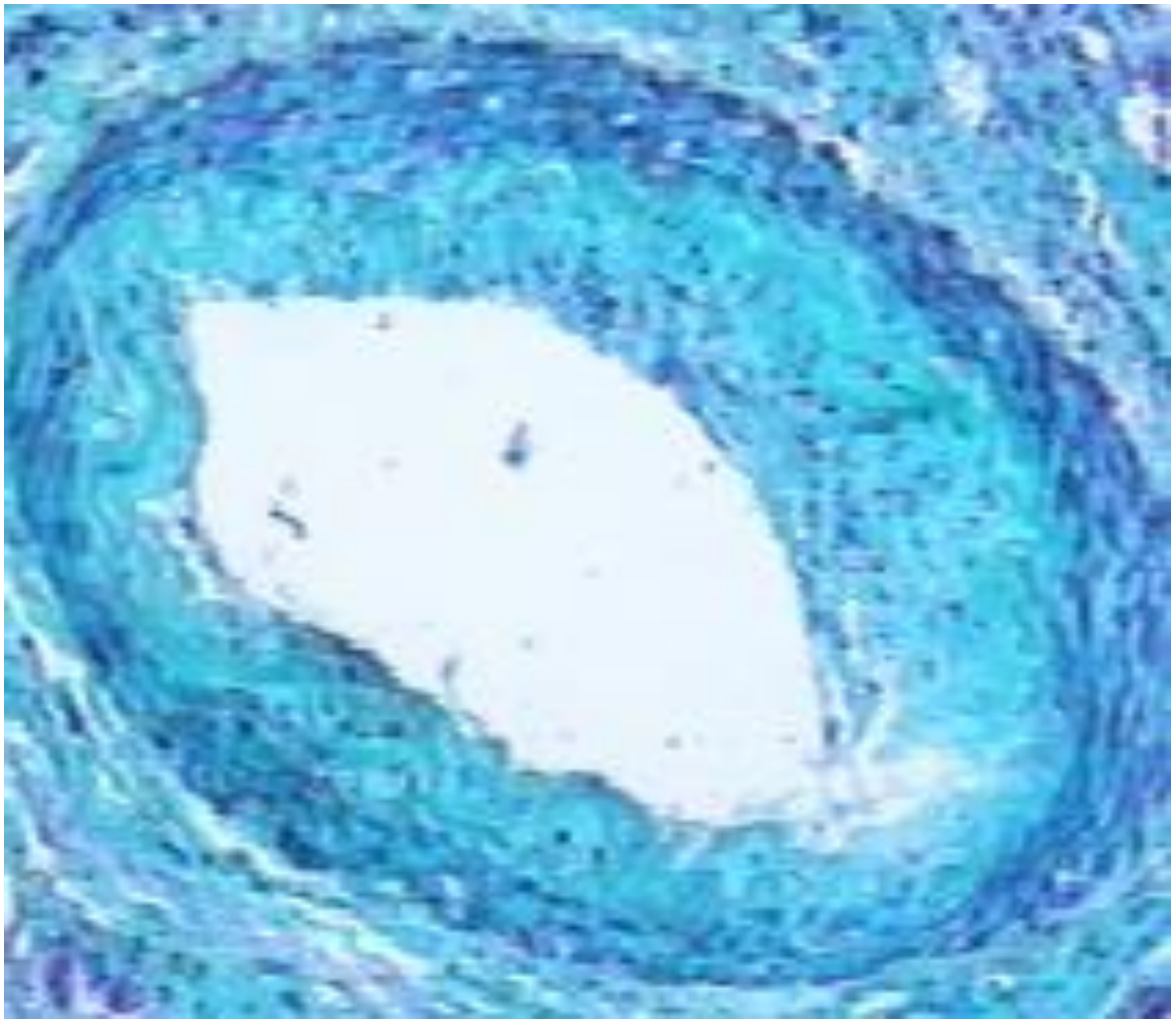

Espessamento Fibroelástico da íntima

Arteríola

Hialinose

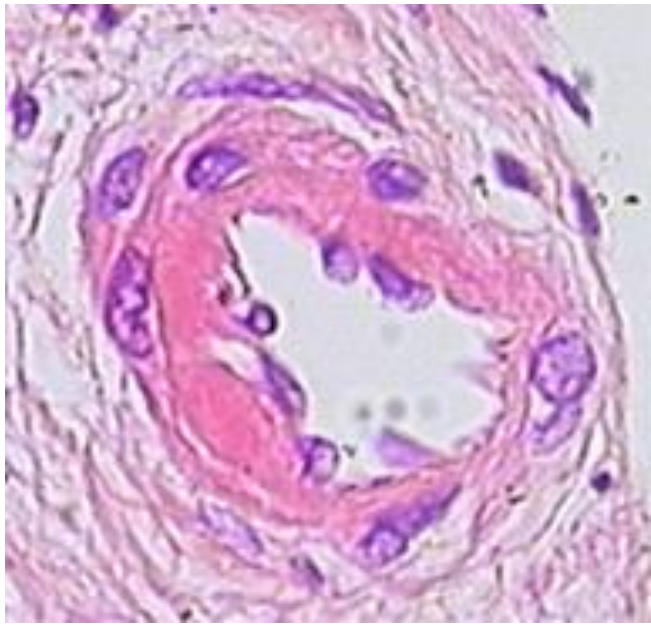

Banco imagens Patge - UFTM

Diabetes *Mellitus*
Hiperglicemia

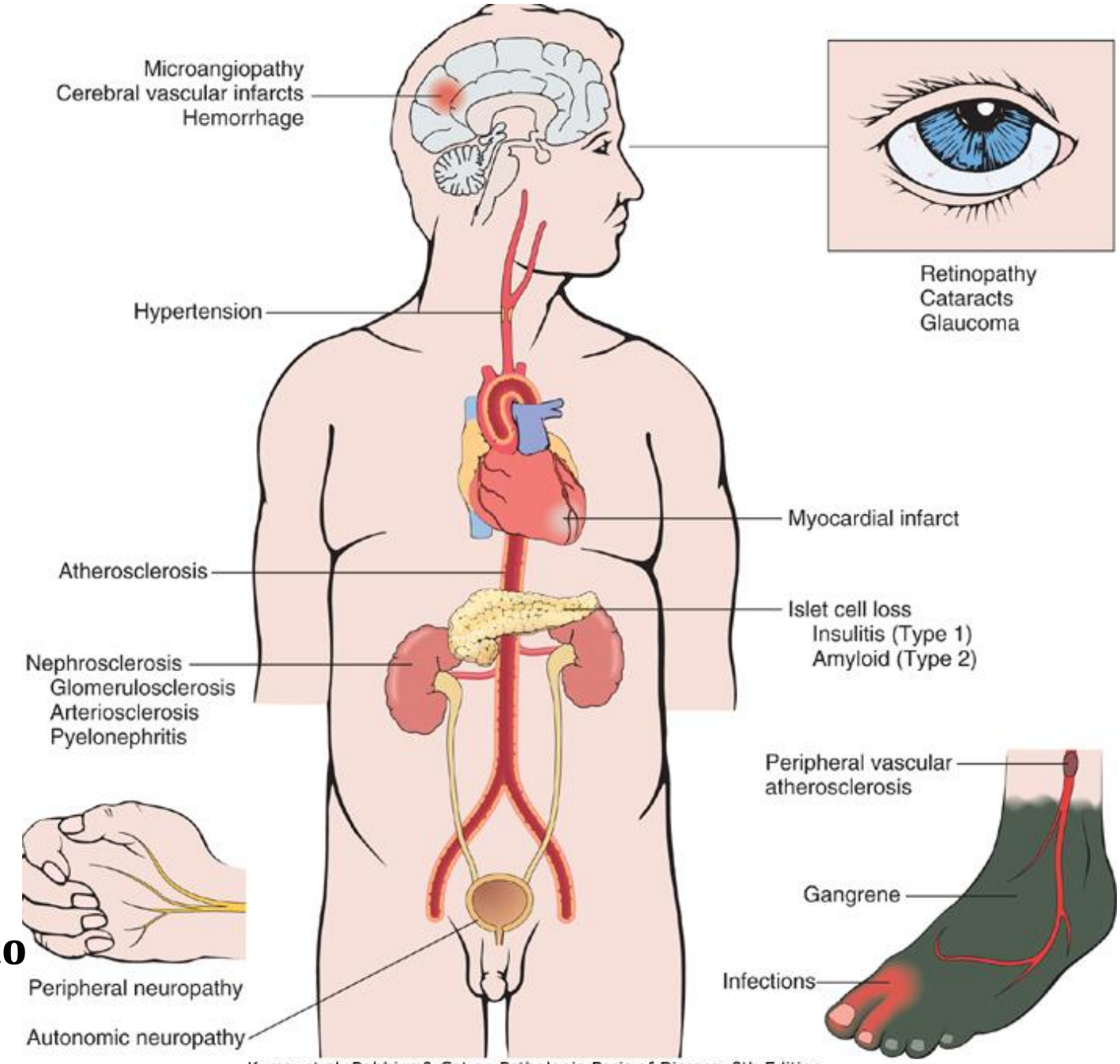

Kumar et al: Robbins & Cotran Pathologic Basis of Disease, 8th Edition.
Copyright © 2009 by Saunders, an imprint of Elsevier, Inc. All rights reserved.

Vaculopatia

Hialinose arteríola
Espes. Fibroelástico
Aterosclerose

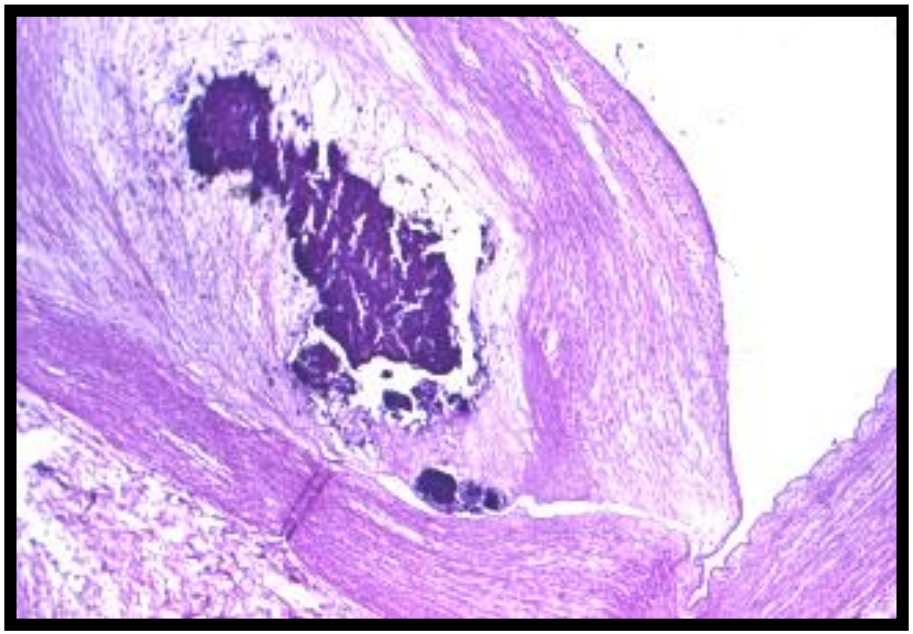

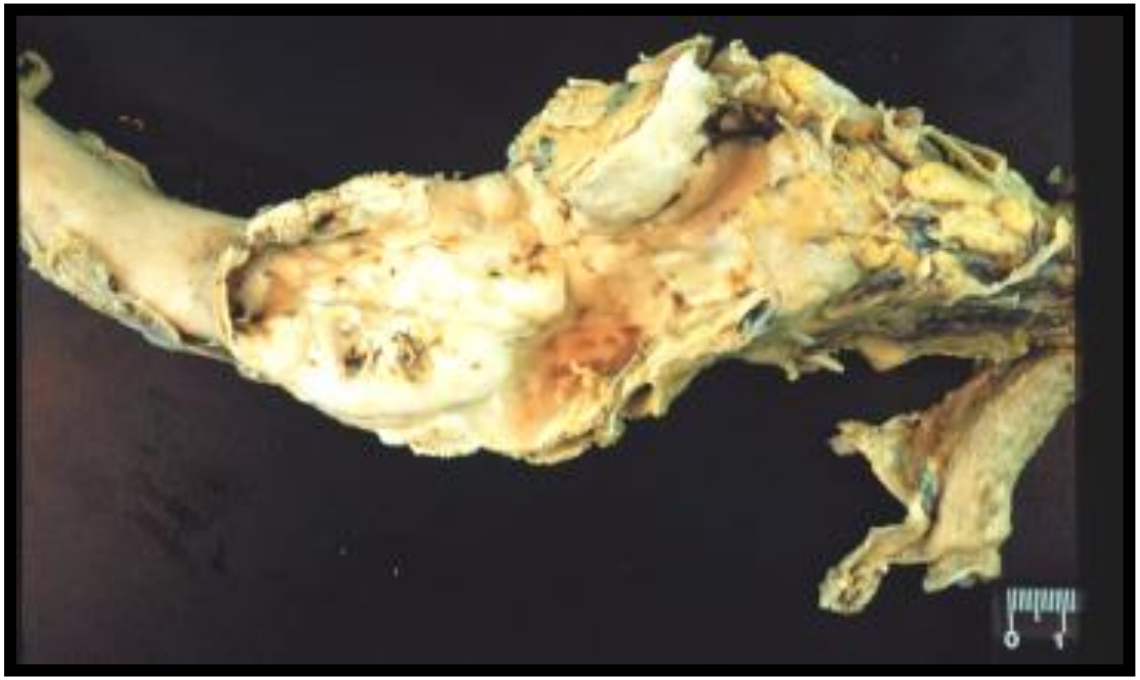

Aterosclerose

Depósito lipídio
Calcificação

Artérias

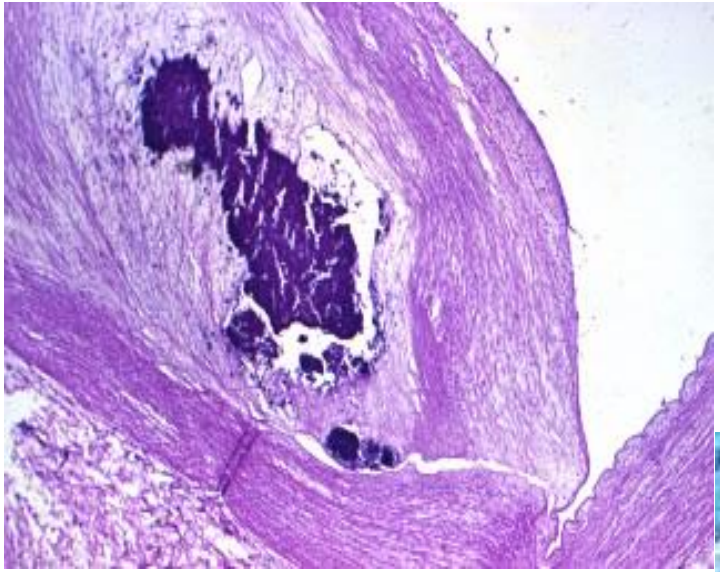

Aterosclerose

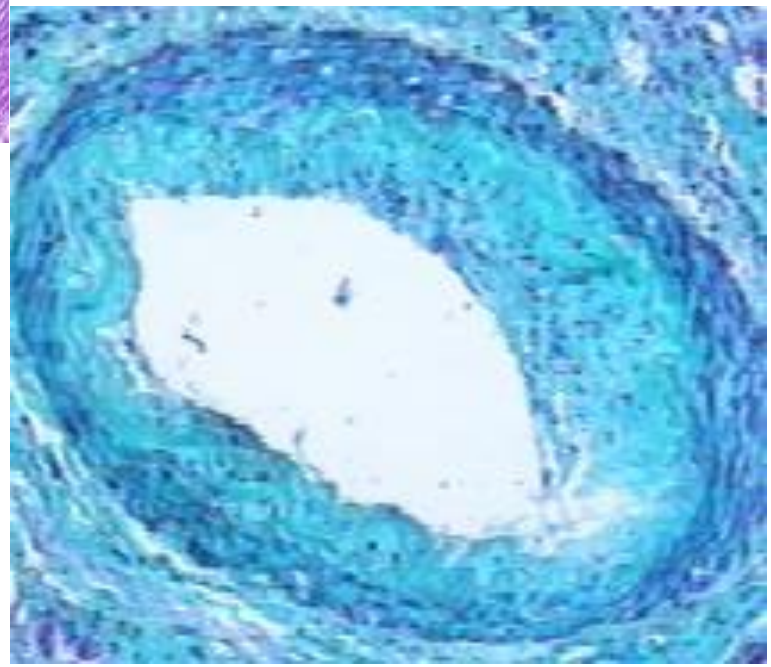

Espessamento
Fibroelástico
da íntima

Arteríola

Hialinose

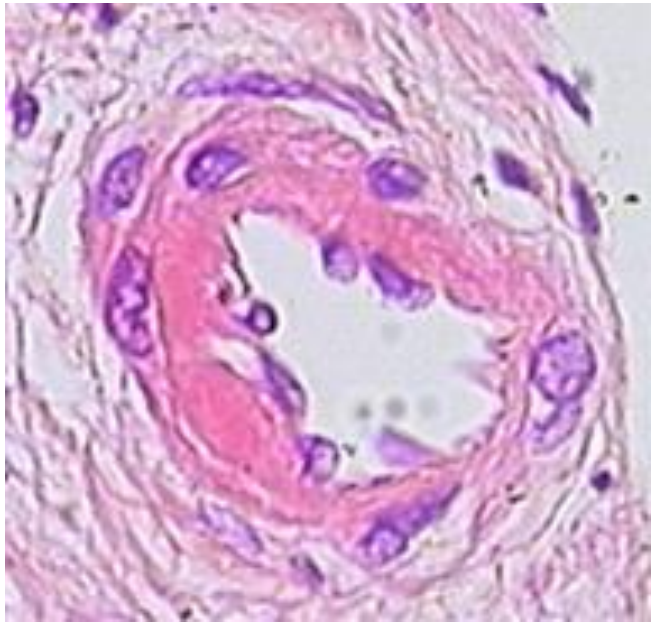

Banco imagens Patge - UFTM

Diabetes *Mellitus*
Hiperglicemia

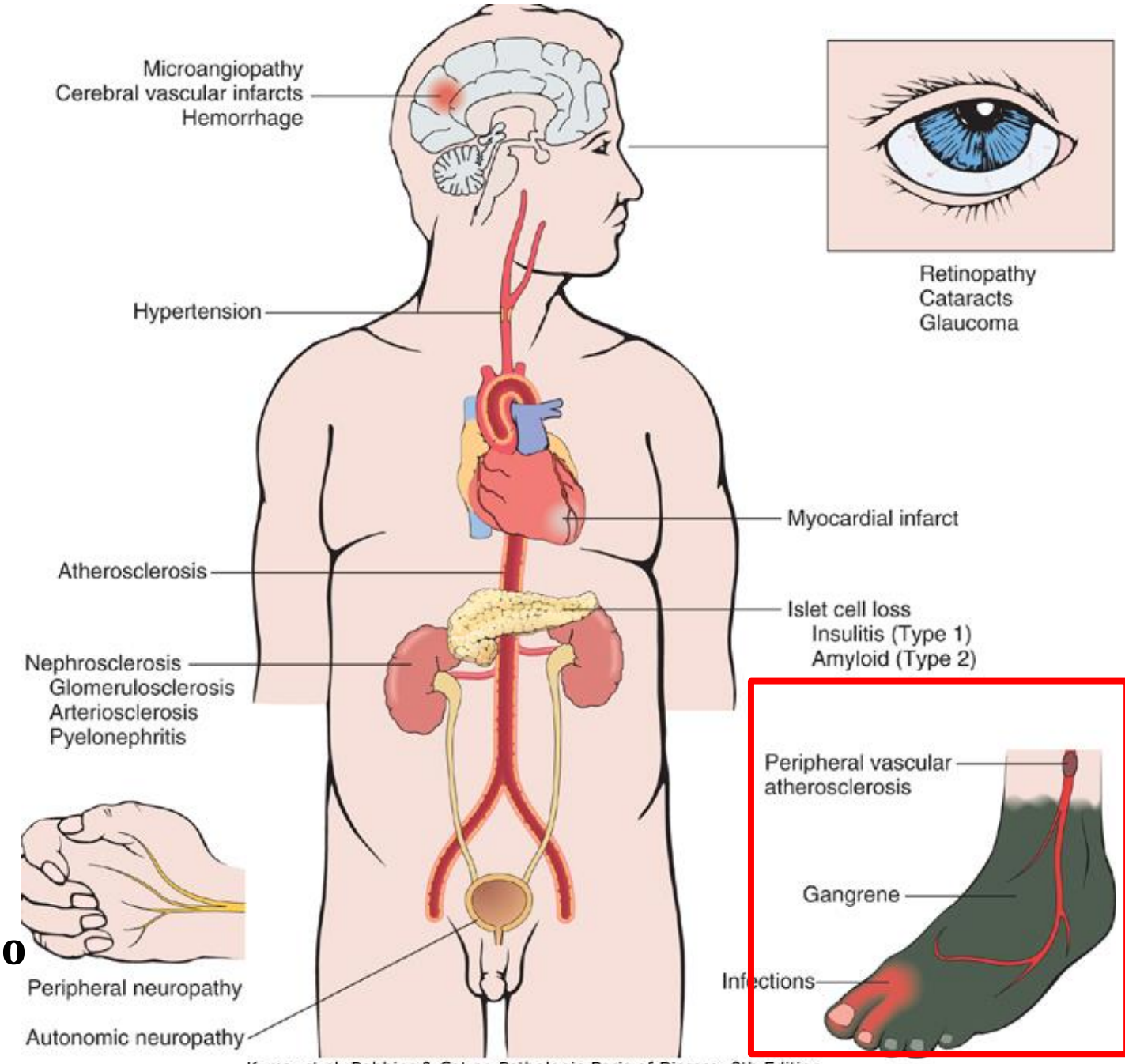

Kumar et al: Robbins & Cotran Pathologic Basis of Disease, 8th Edition.
Copyright © 2009 by Saunders, an imprint of Elsevier, Inc. All rights reserved.

Vaculopatia

Hialinose arteríola
Espes. Fibroelástico
Aterosclerose

Diabetes *Mellitus*
Hiperglicemia

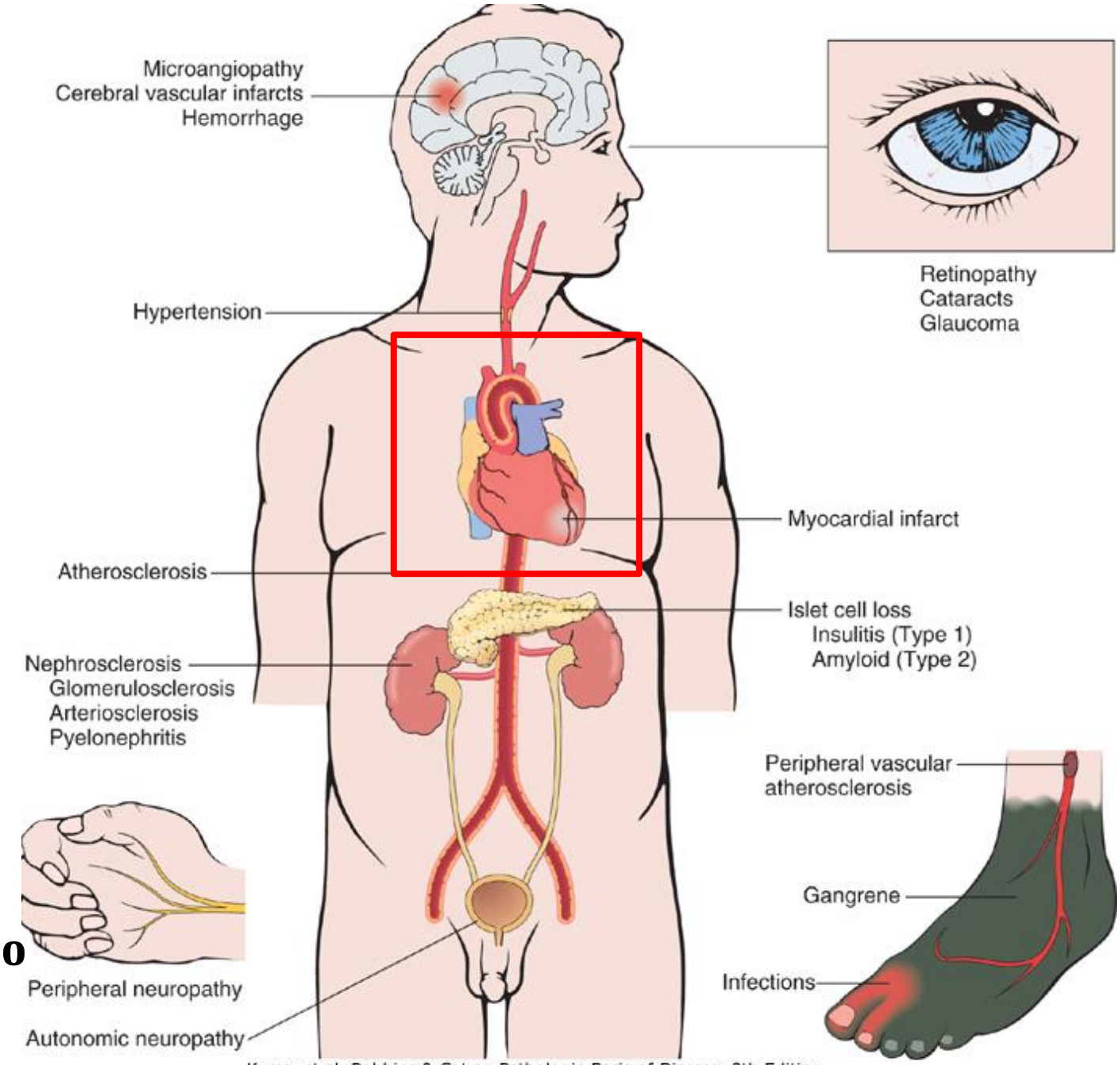

Kumar et al: Robbins & Cotran Pathologic Basis of Disease, 8th Edition.
Copyright © 2009 by Saunders, an imprint of Elsevier, Inc. All rights reserved.

Vaculopatia

Hialinose arteríola
Espes. Fibroelástico
Aterosclerose

Diabetes *Mellitus*
Hiperglicemia

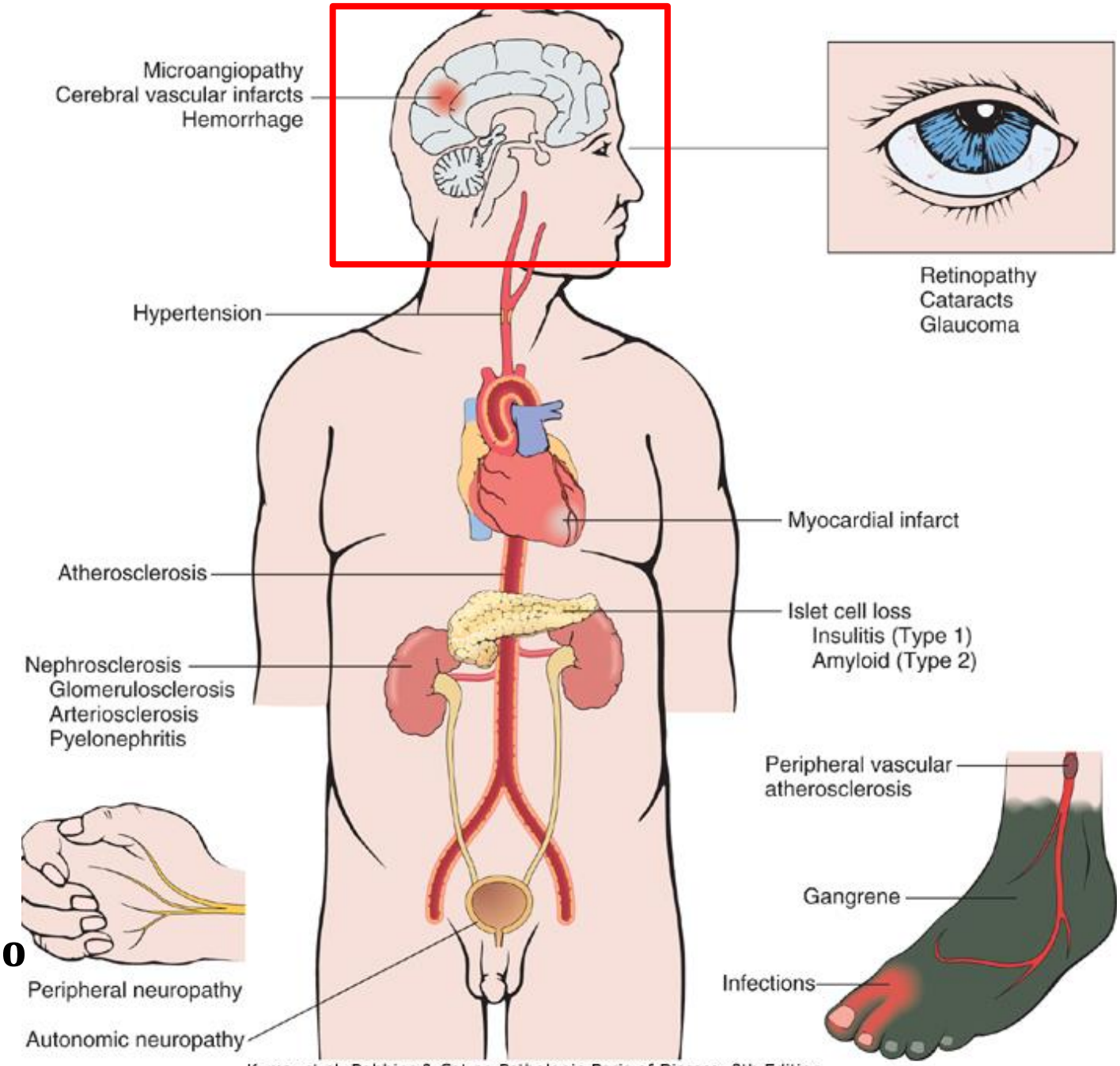

Kumar et al: Robbins & Cotran Pathologic Basis of Disease, 8th Edition.
Copyright © 2009 by Saunders, an imprint of Elsevier, Inc. All rights reserved.

Vaculopatia

Hialinose arteríola
Espes. Fibroelástico
Aterosclerose

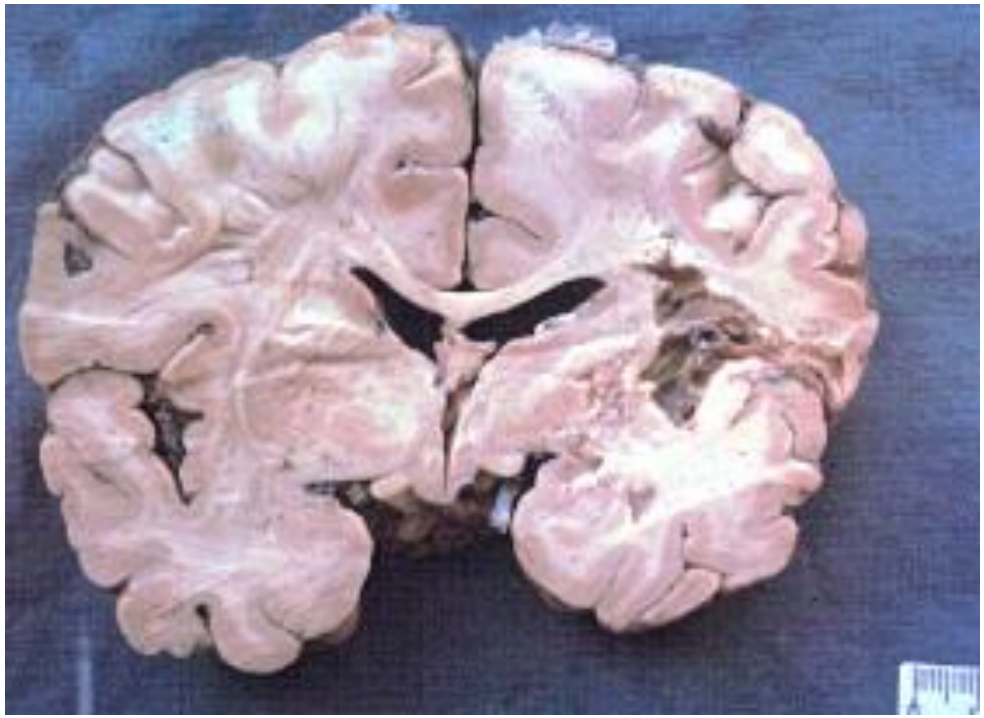

Diabetes *Mellitus*
Hiperglicemia

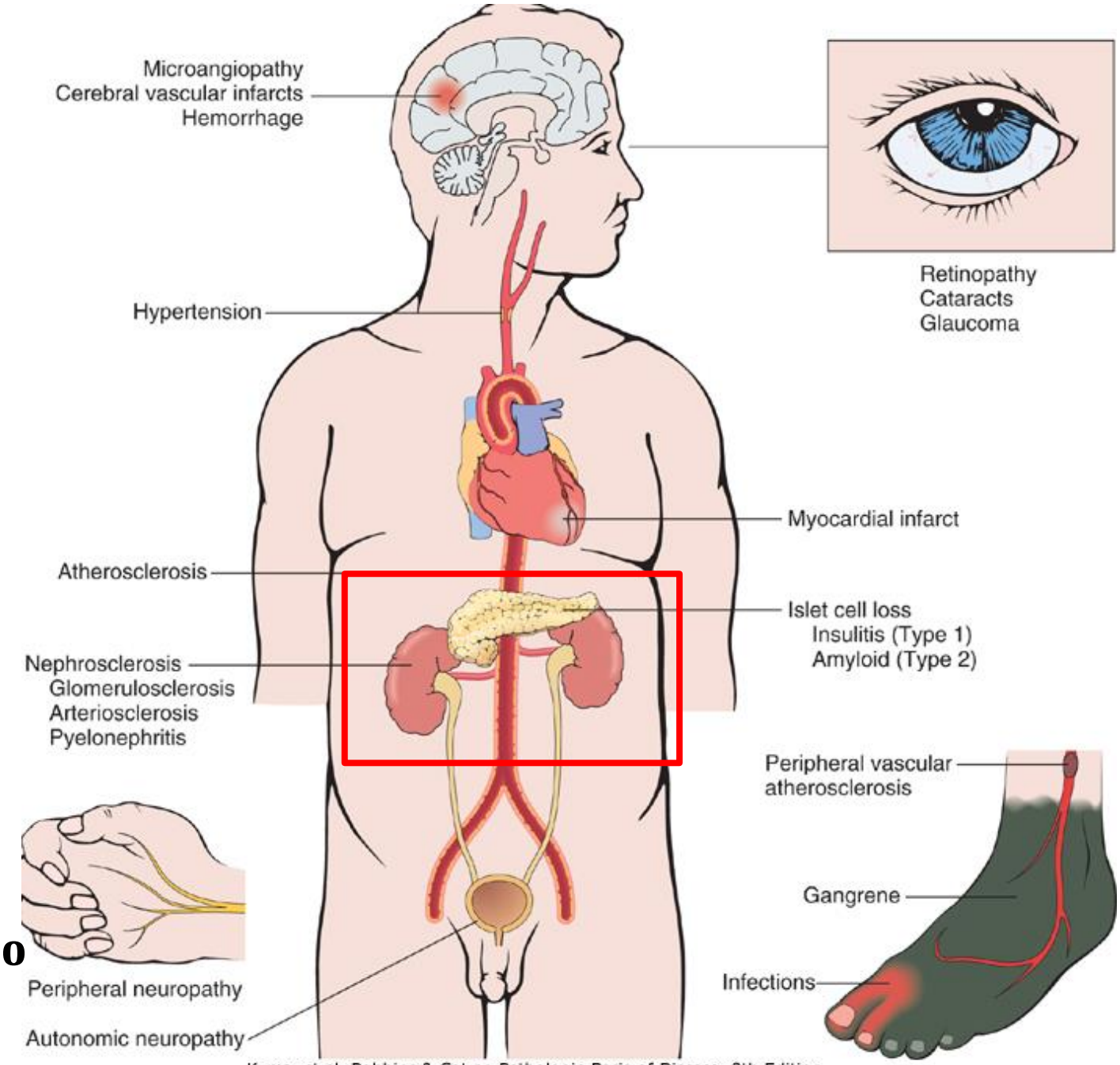

Kumar et al: Robbins & Cotran Pathologic Basis of Disease, 8th Edition.
Copyright © 2009 by Saunders, an imprint of Elsevier, Inc. All rights reserved.

Vaculopatia

Hialinose arteríola
Espes. Fibroelástico
Aterosclerose

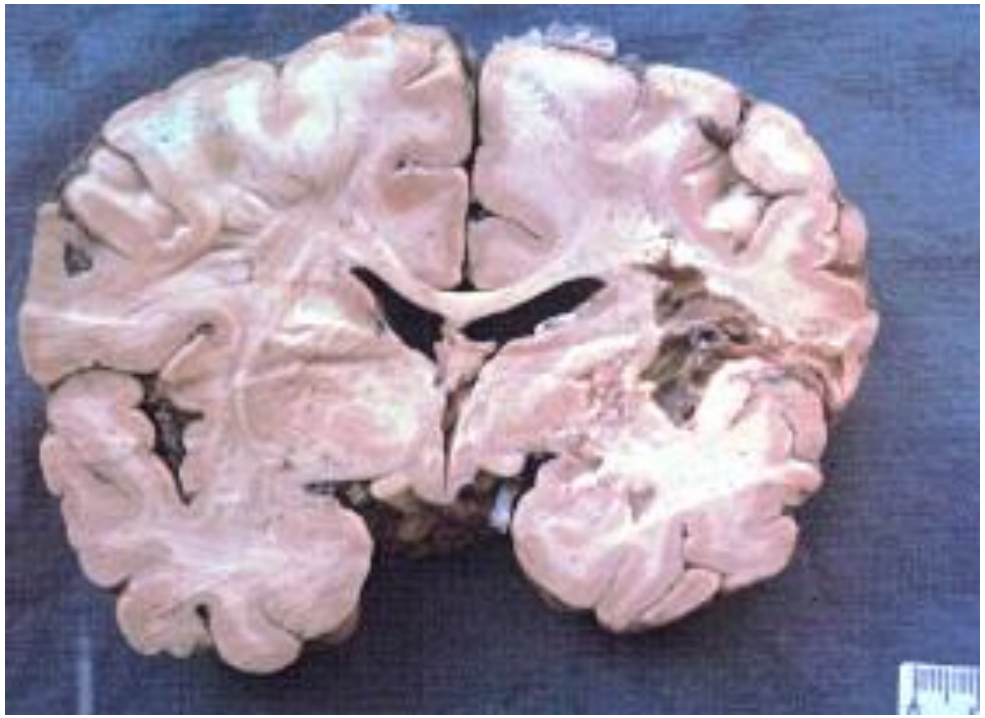

N4184

Diabetes *Mellitus*
Hiperglicemia

Nefropatia
Retinopatia
Neuropatia

Vaculopatia

↑ **Membrana basal**

Hialinose arteríola
Espes. Fibroelástico
Aterosclerose

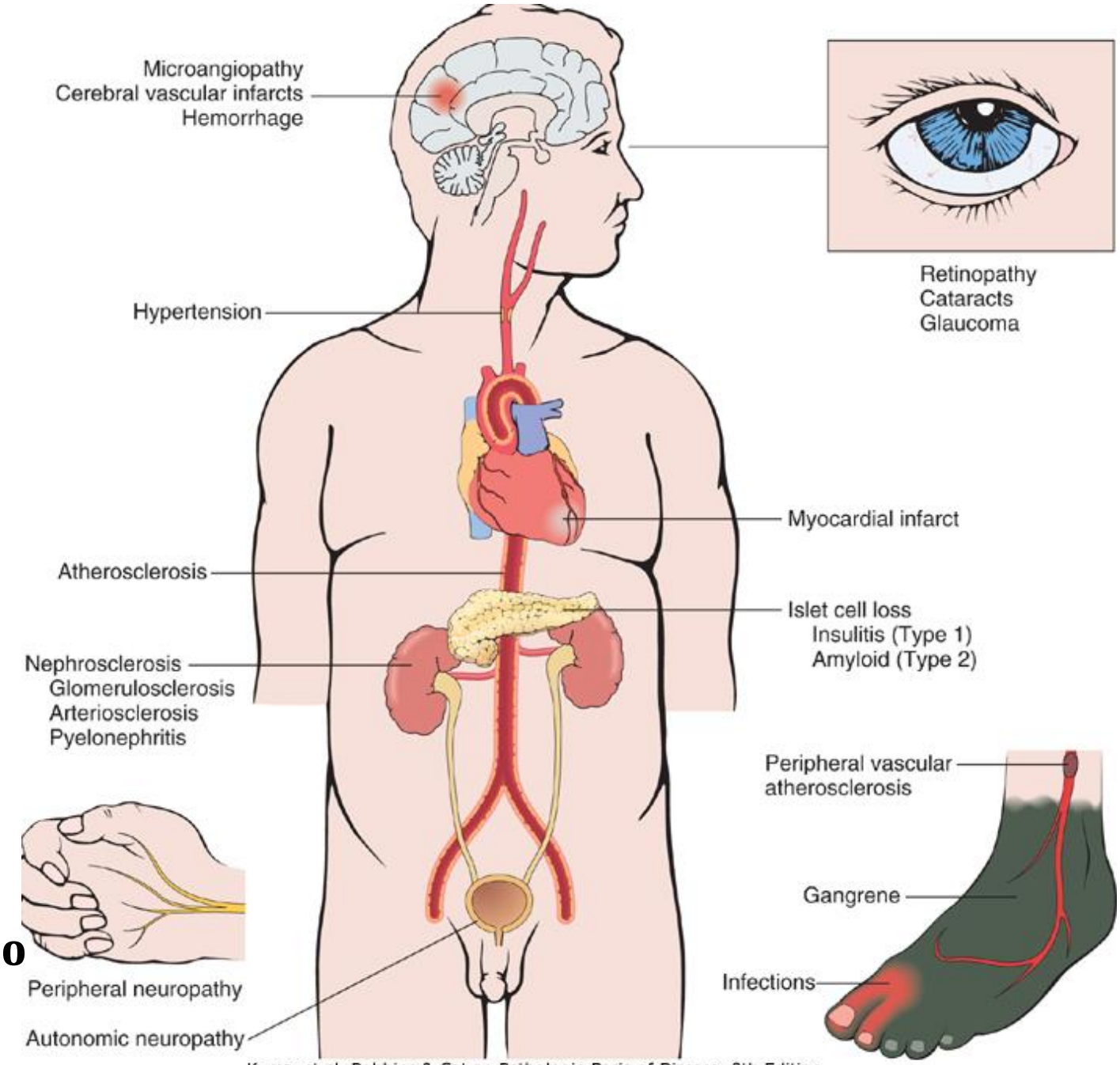

Kumar et al: Robbins & Cotran Pathologic Basis of Disease, 8th Edition.
Copyright © 2009 by Saunders, an imprint of Elsevier, Inc. All rights reserved.

Nefropatia Diabética

→ 1ª - causa mundial de Doença Renal de Estágio Final

USRDS, 2002

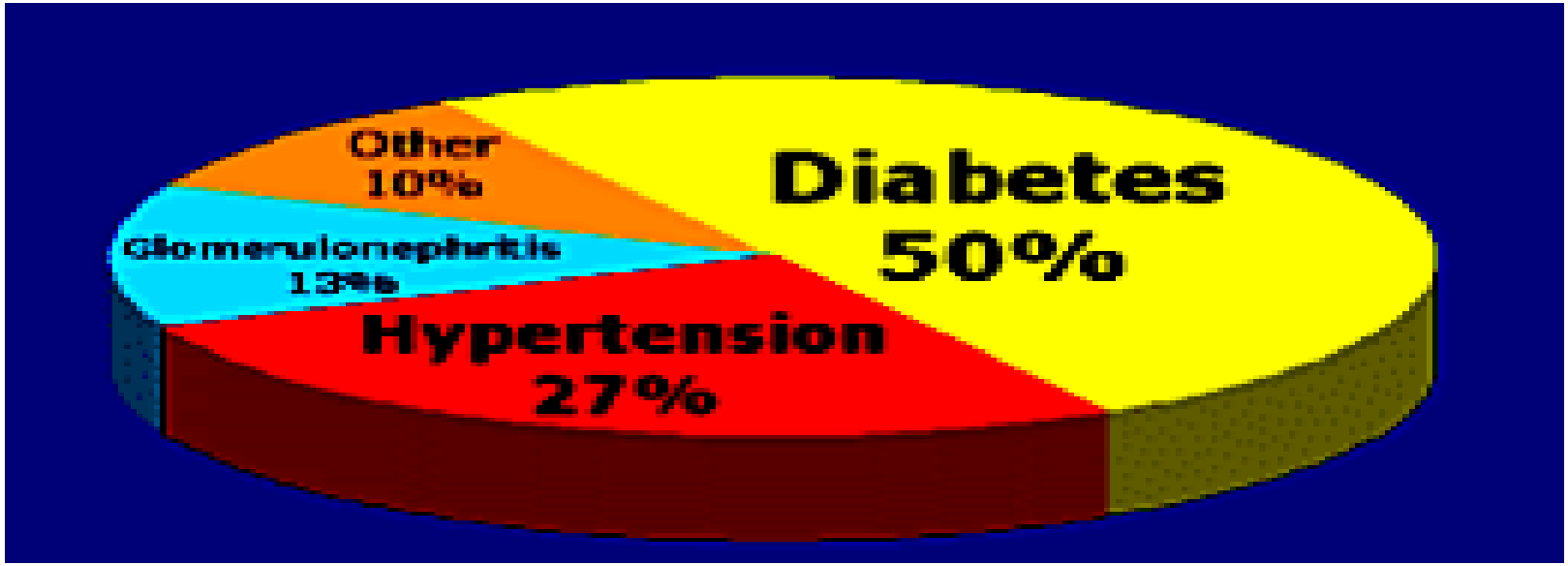

Nefropatia

-Associada a alta morbidade e mortalidade

- maioria mortes em diabéticos - nefropatia, muitas são cardiovasculares e não causa renal diretamente

Mecanismos

- Hiperglicemia
- Alterações vasculares
- Hemodinâmicas - Hiperfiltração

Compartimentos

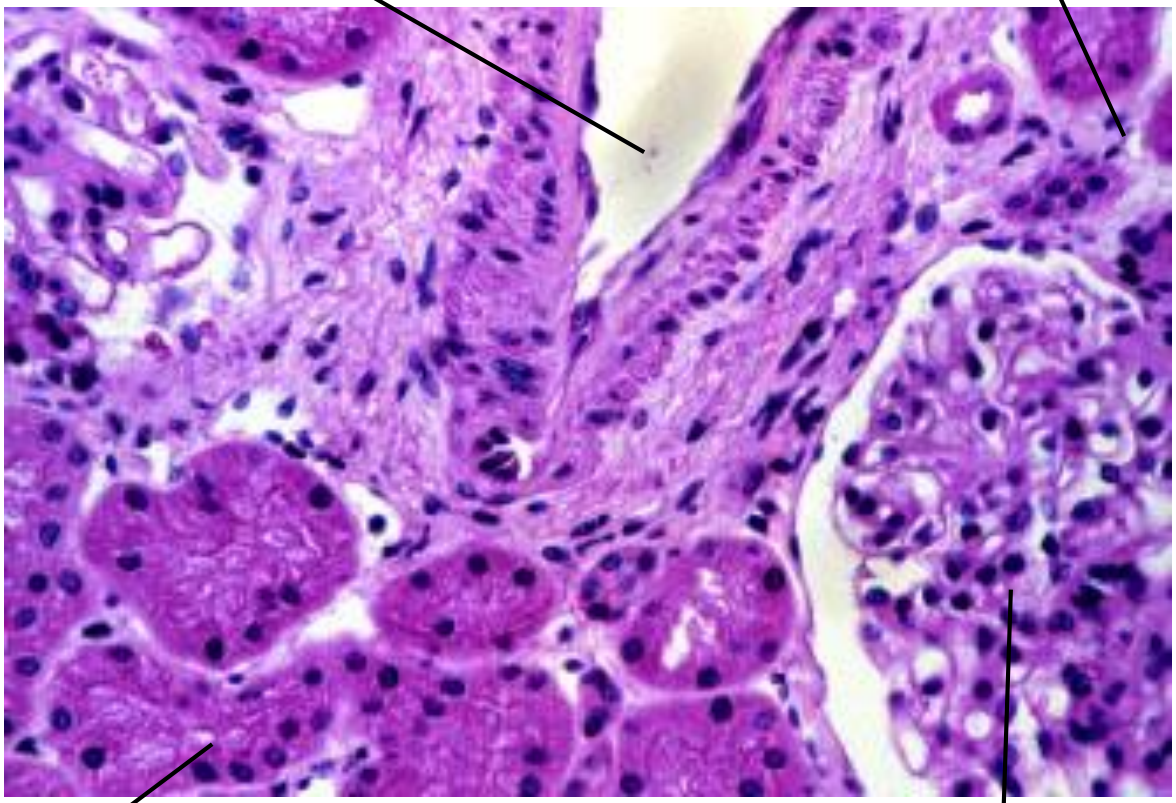

Biópsia renal percutânea

ME – glutaraldeido ou Karnovosky
+ vermelho de rutênio

IF

10 glomérulos

ML – Paraformaldeído



2 µm



Compartmentos

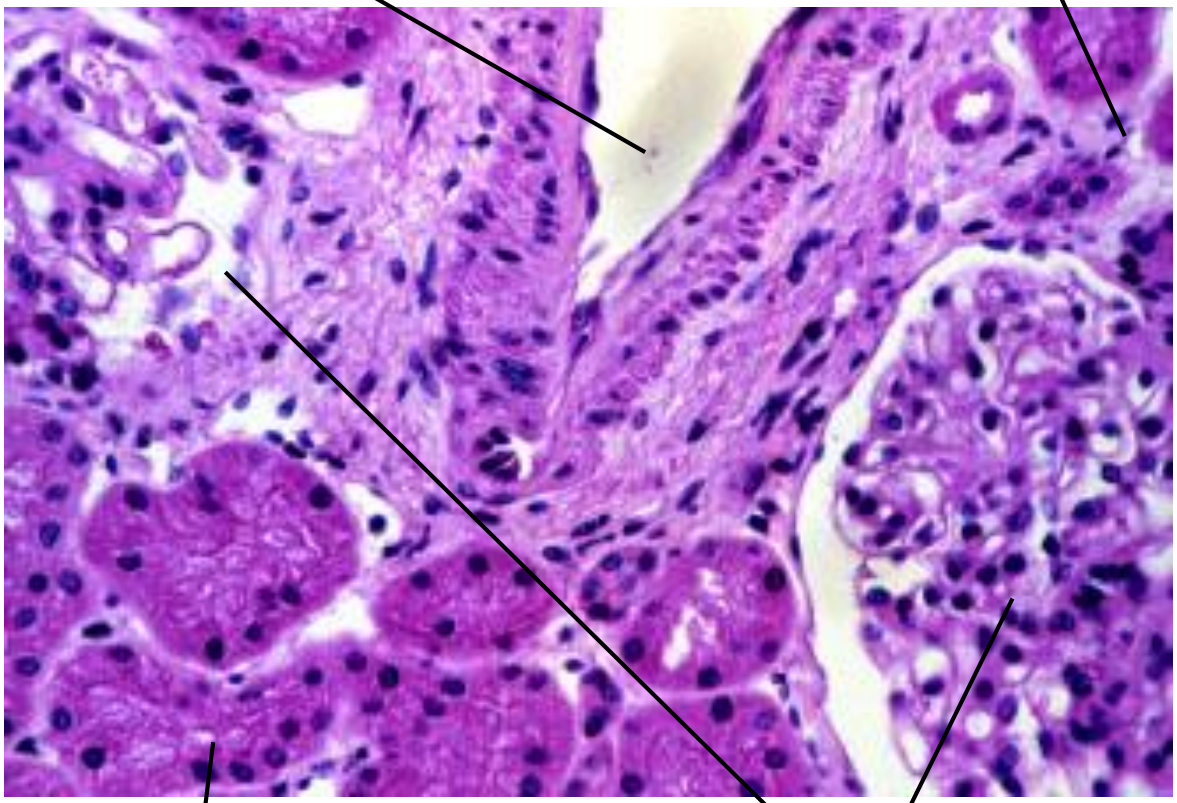

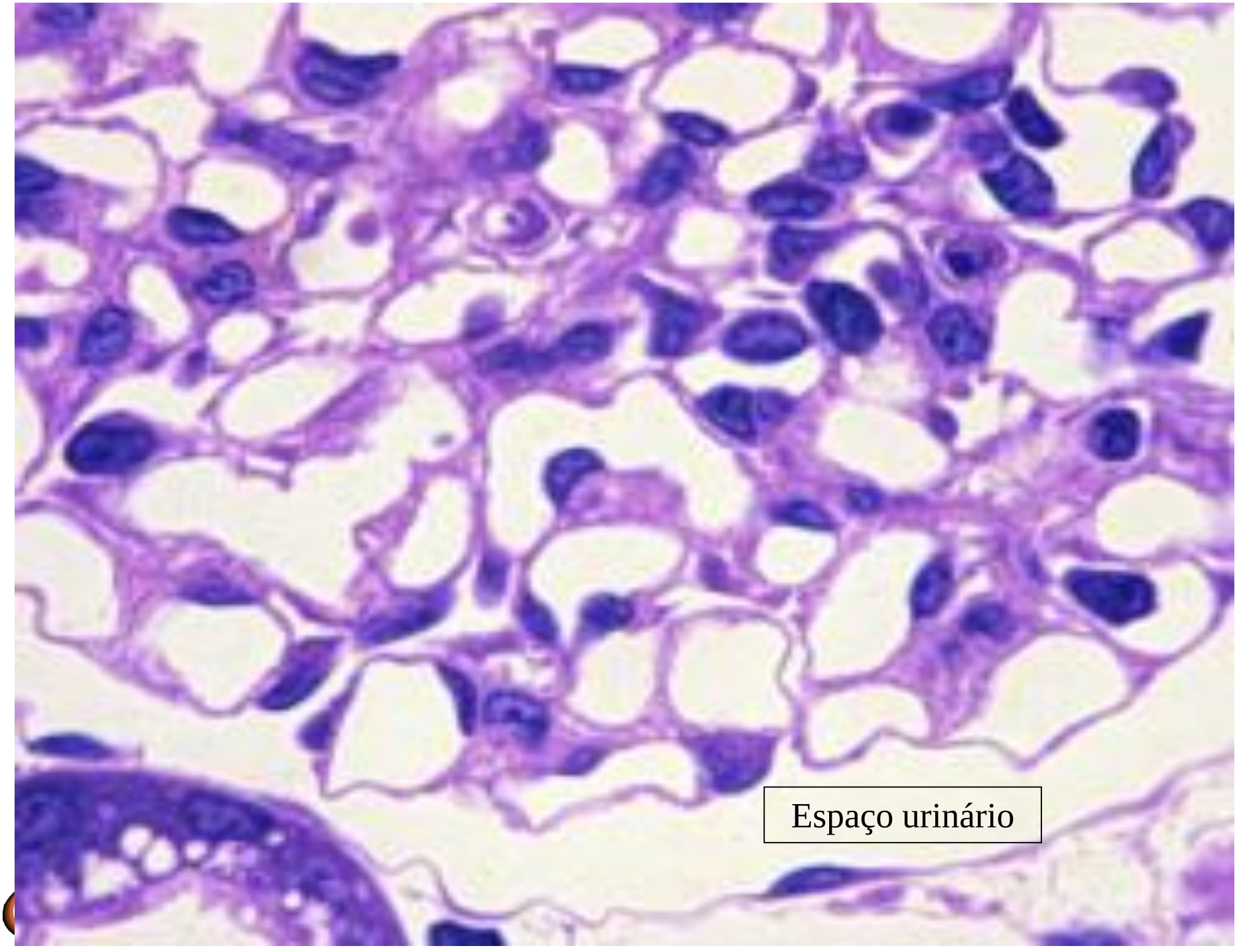
Espaço urinário

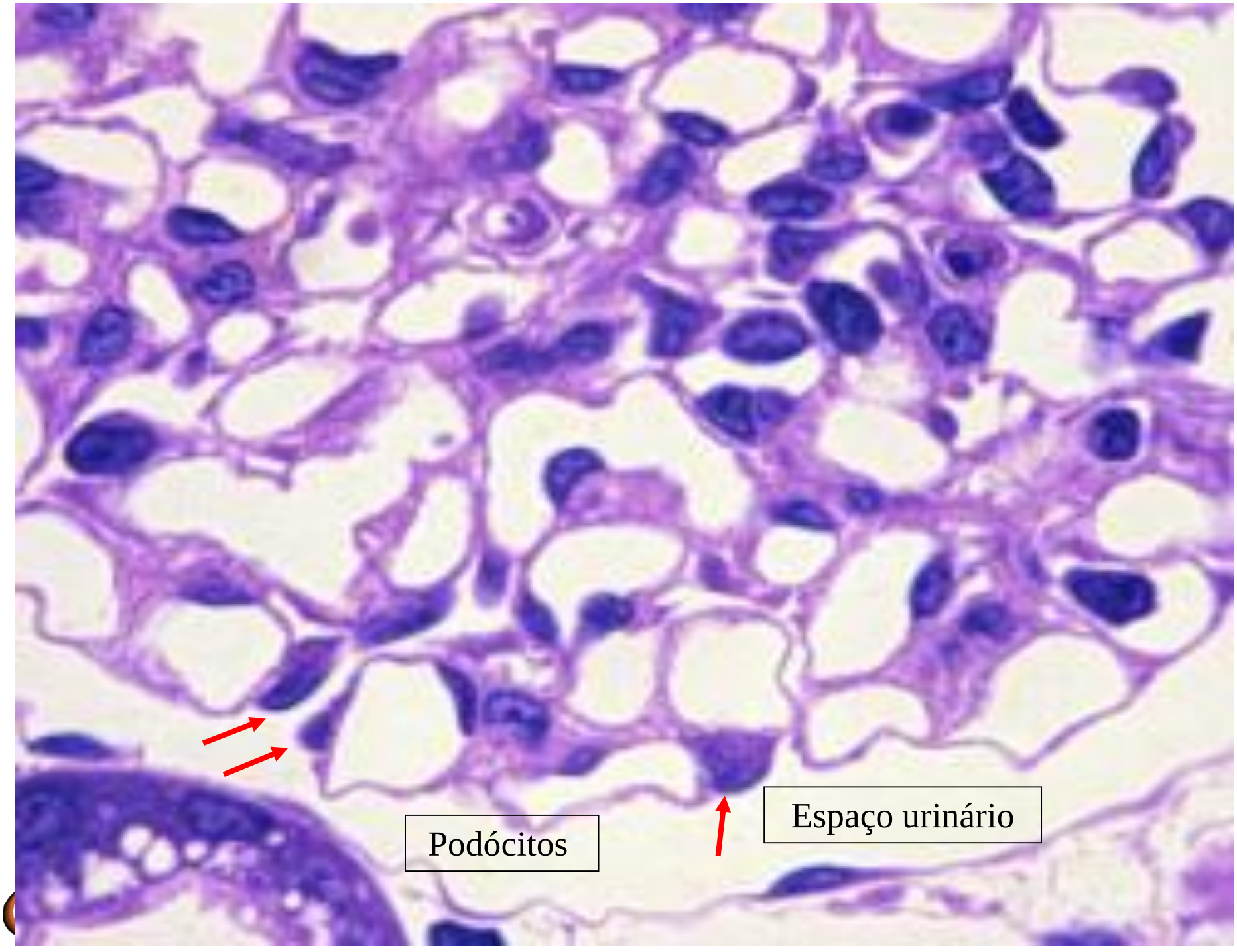
Podócitos
Espaço urinário

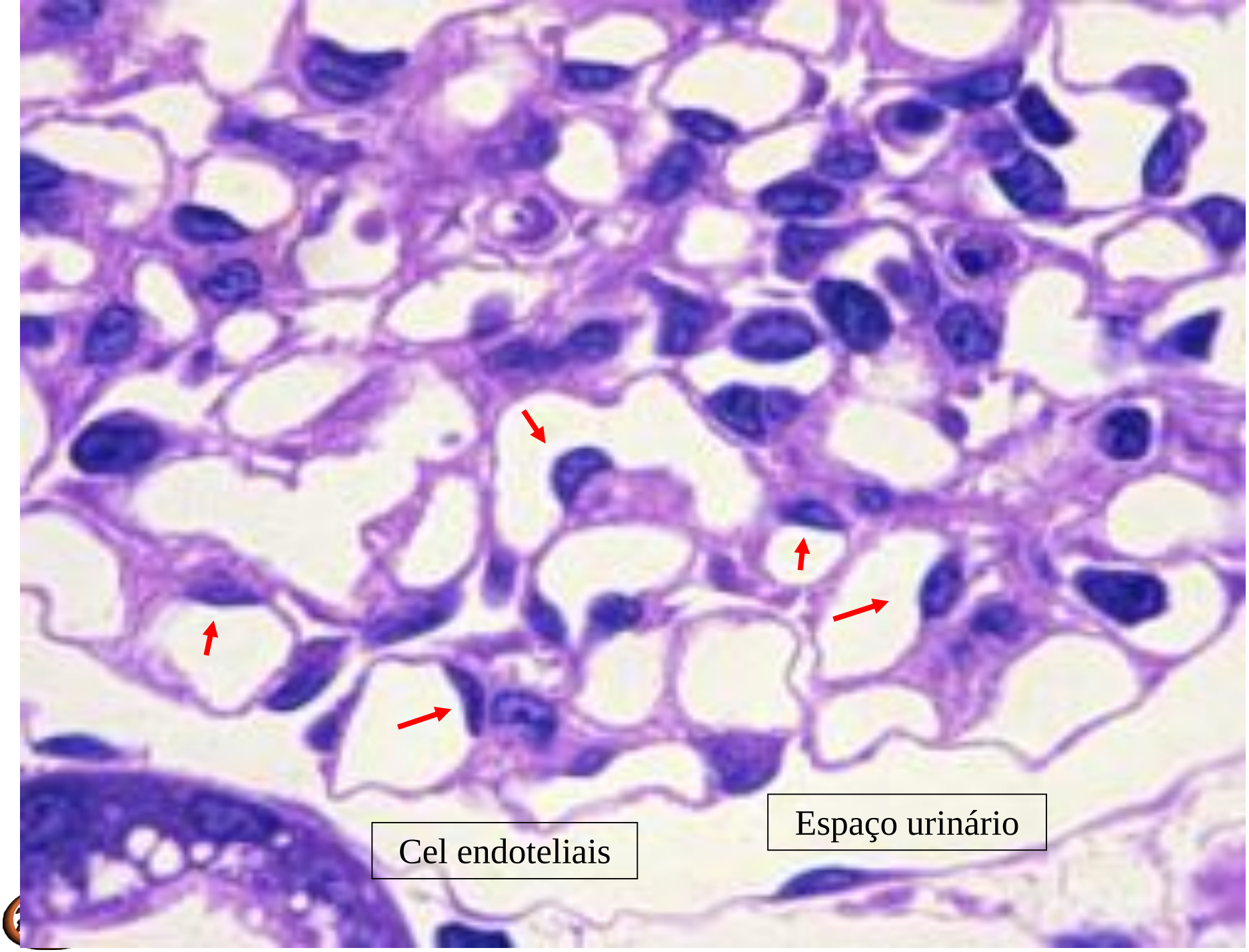
Cel endoteliais
Espaço urinário

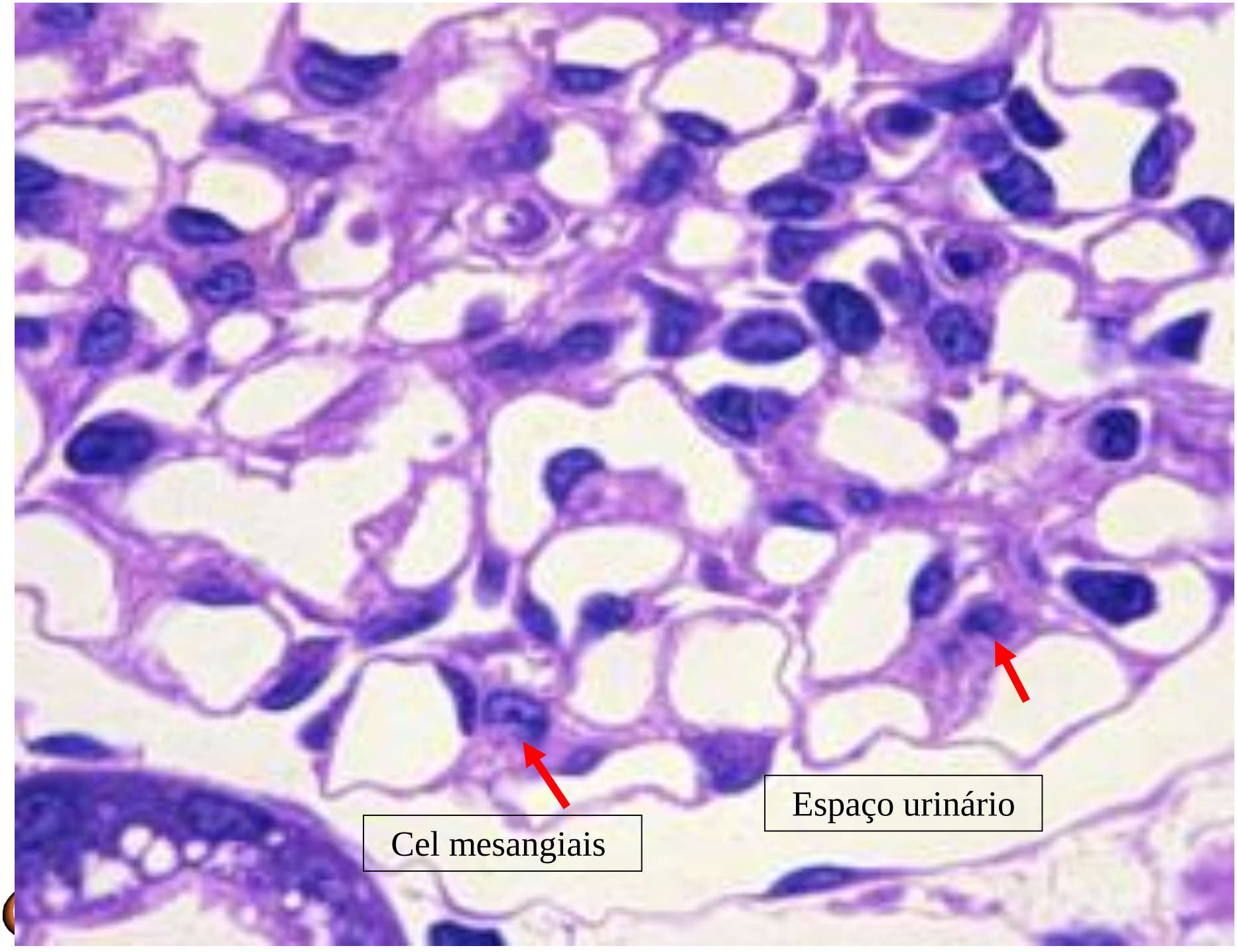
Espaço urinário
Cel mesangiais

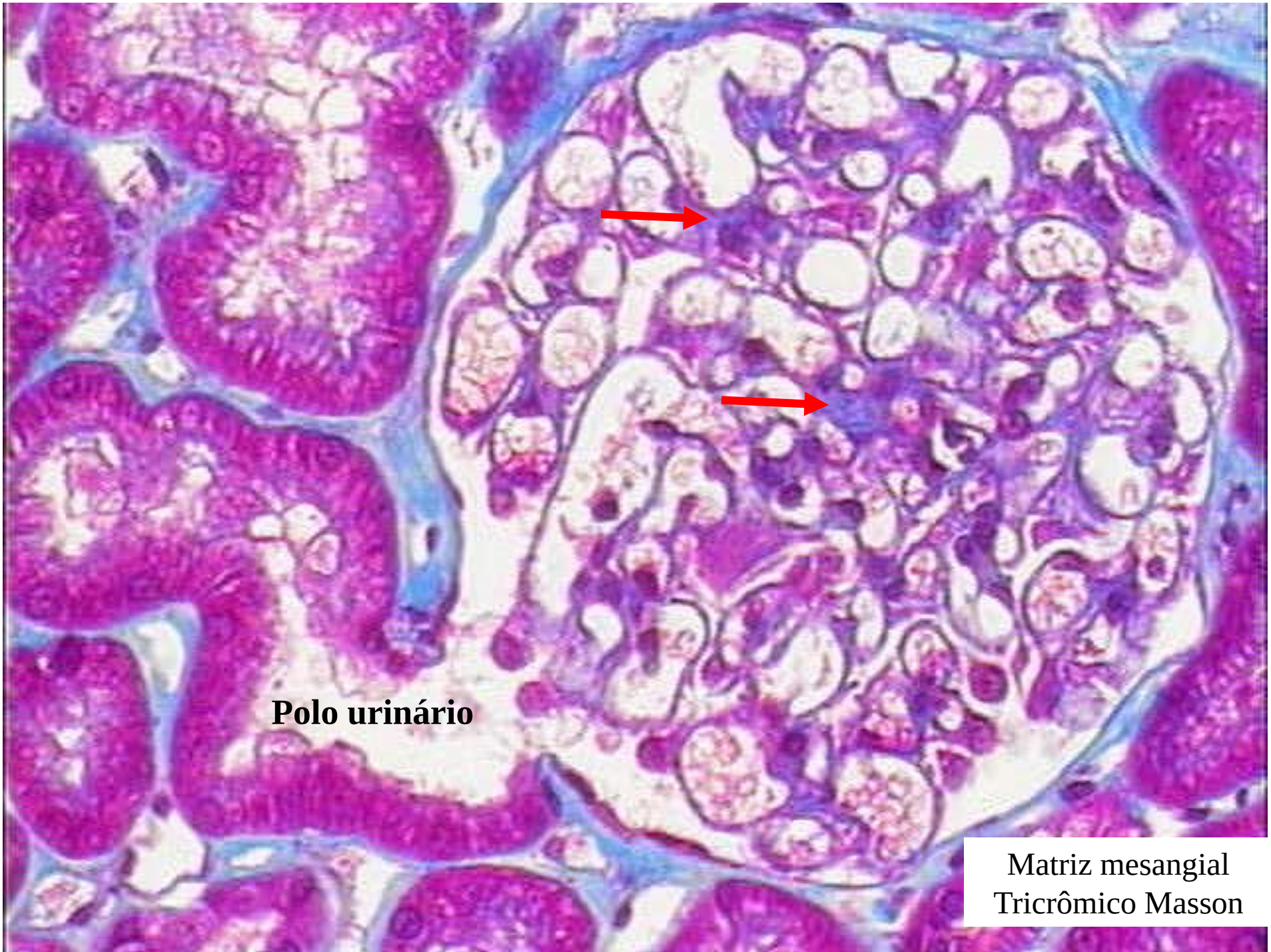

Matriz mesangial
Tricrômico Masson

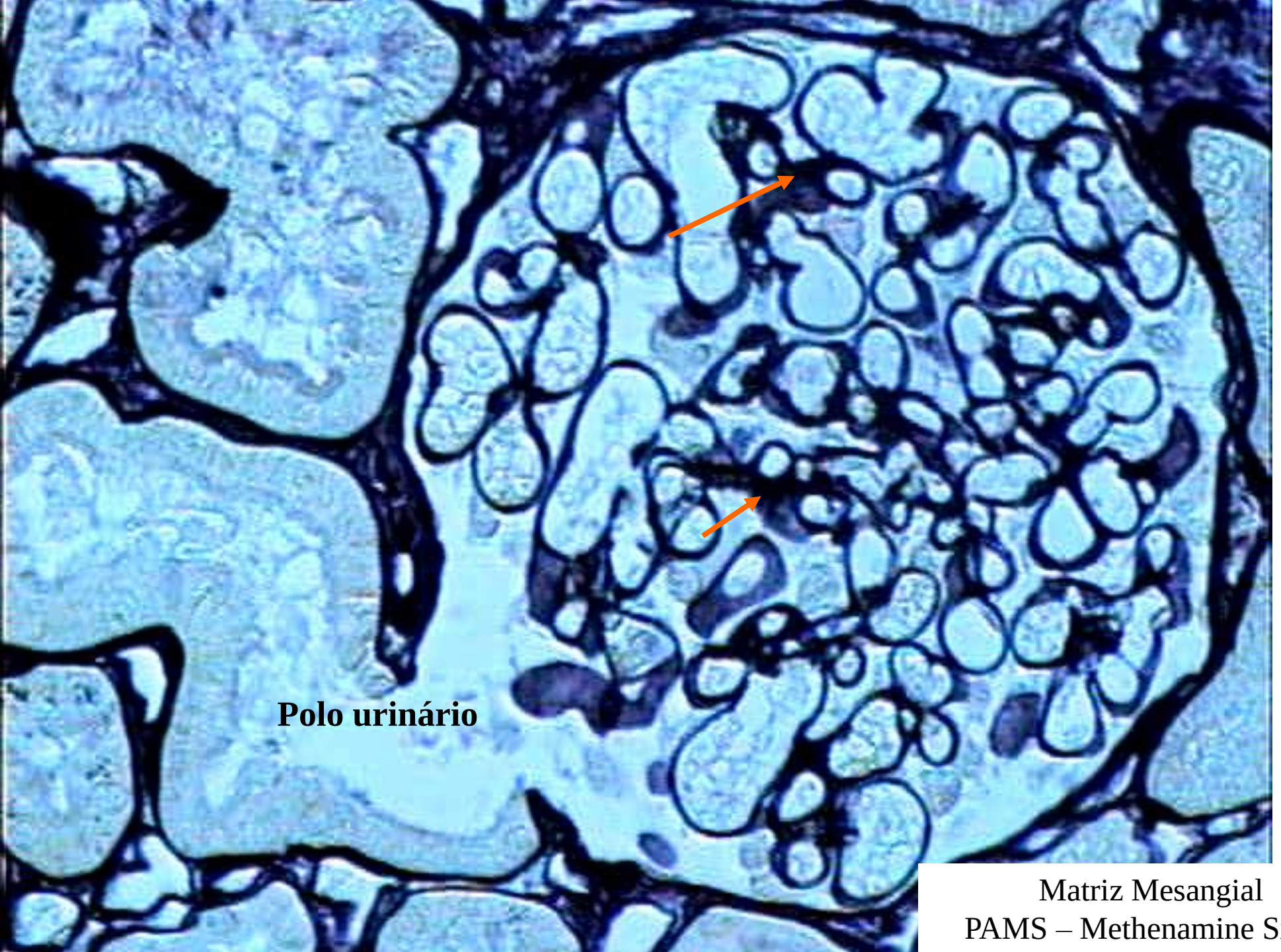

Matriz Mesangial
PAMS – Methenamine Silver

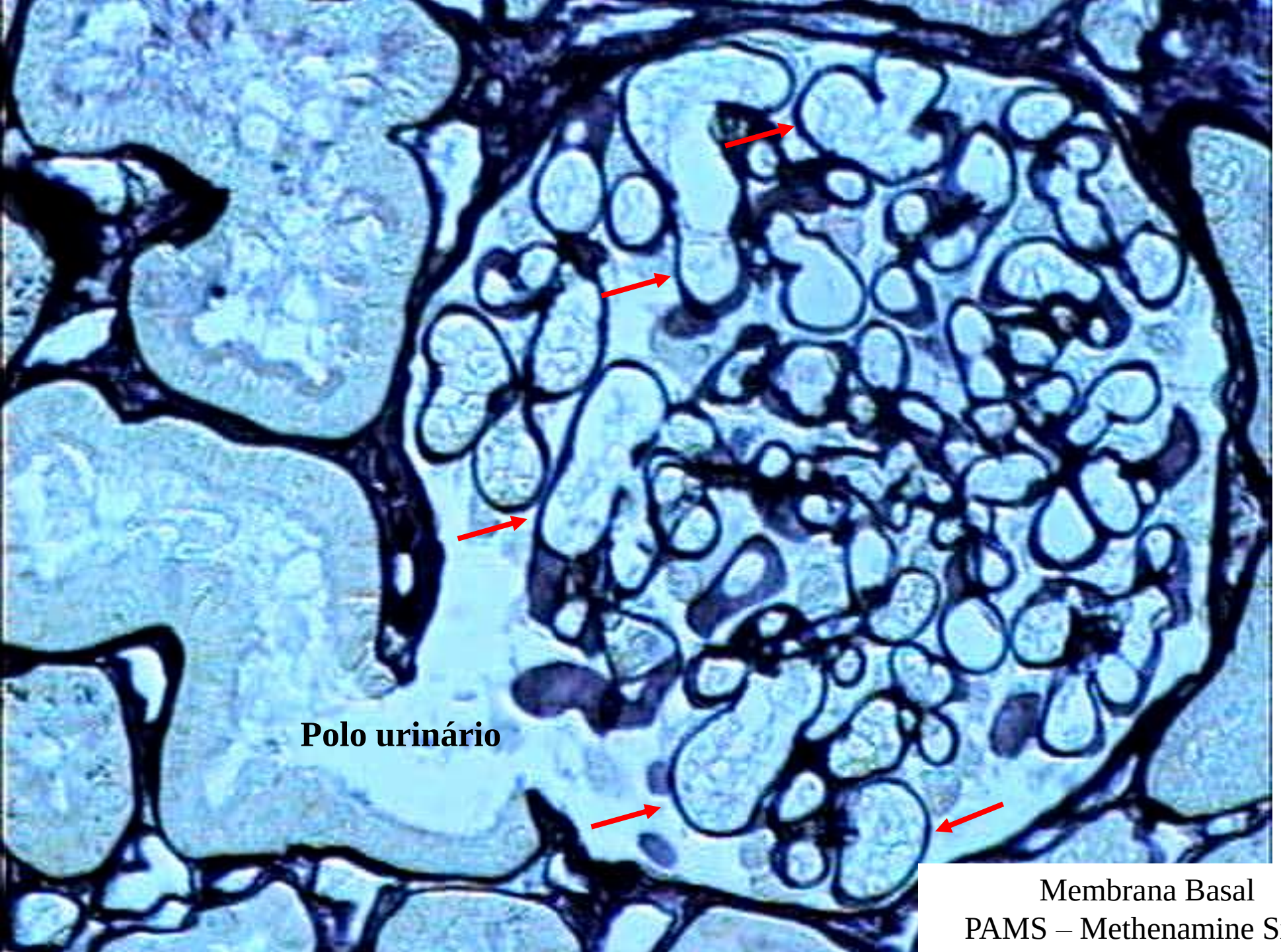

Membrana Basal
PAMS – Methenamine Silver

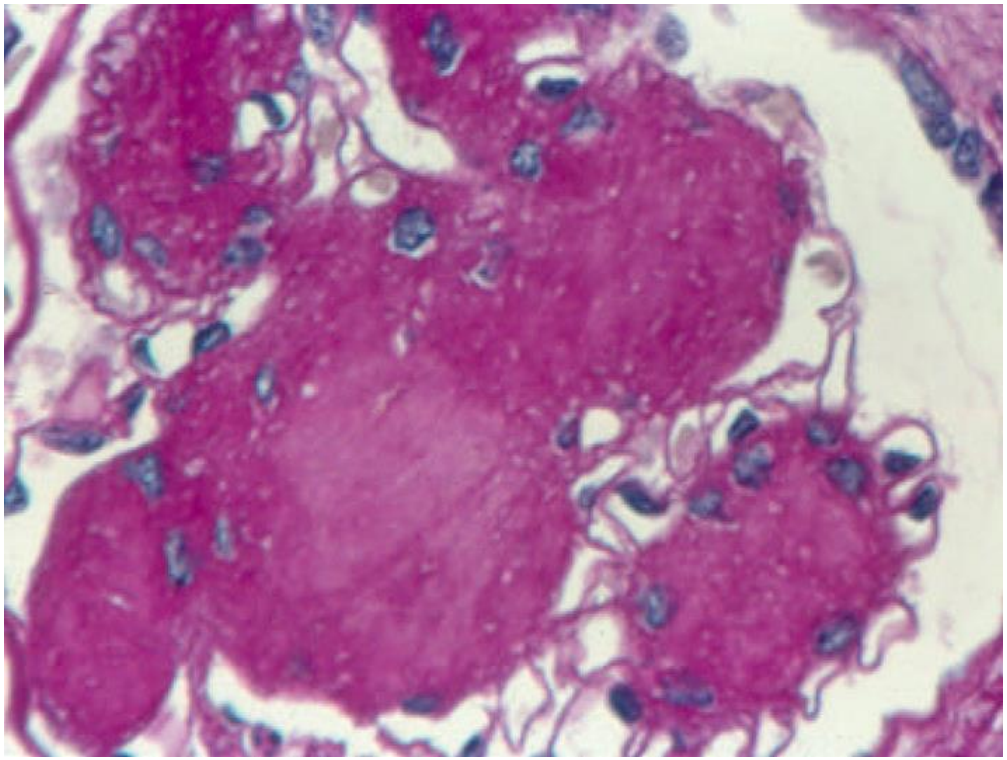

PAS +

BR070208

PAMS+, 820X

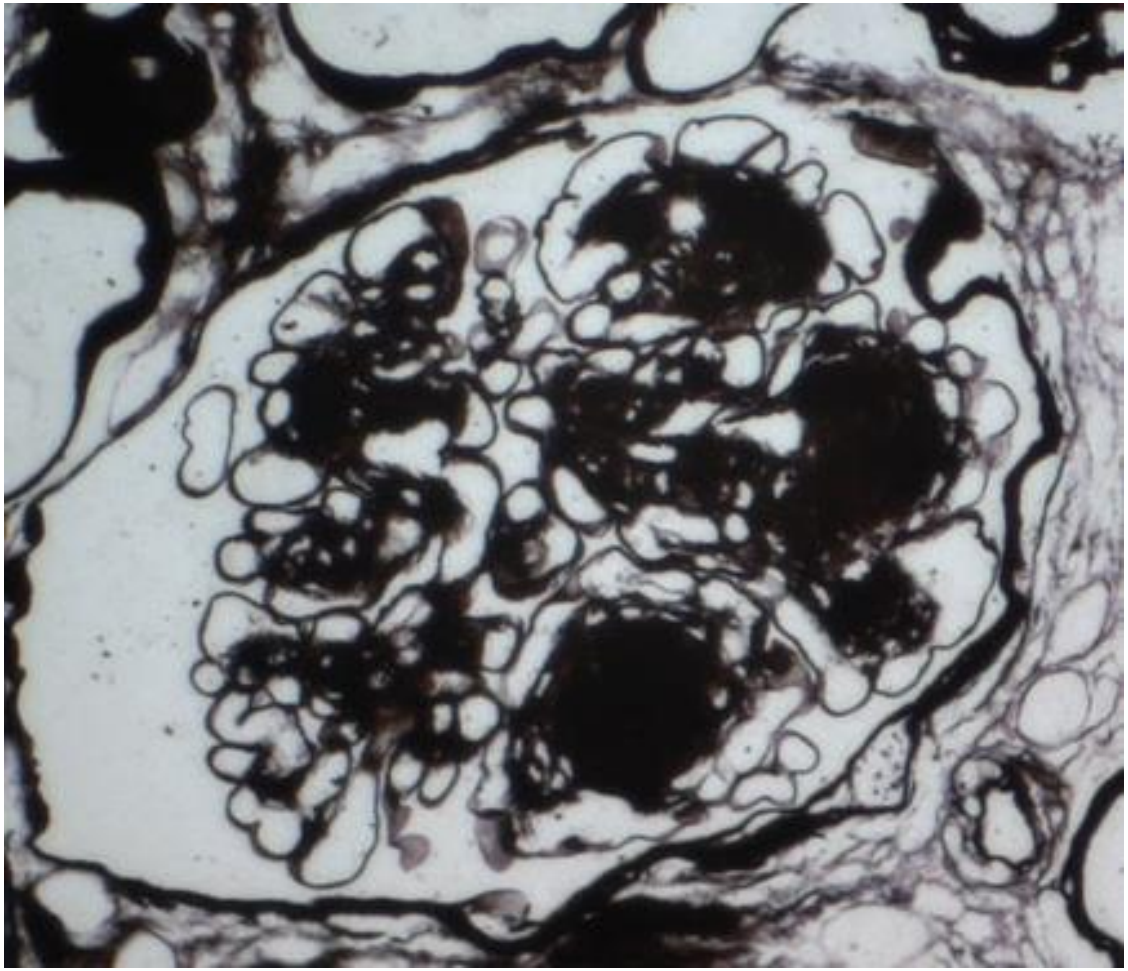

Fioretto & Mauer, 2007

Hiperglicemia

- glicação não enzimática
- AGES – produtos finais da glicação avançada
- Glucose – sorbitol

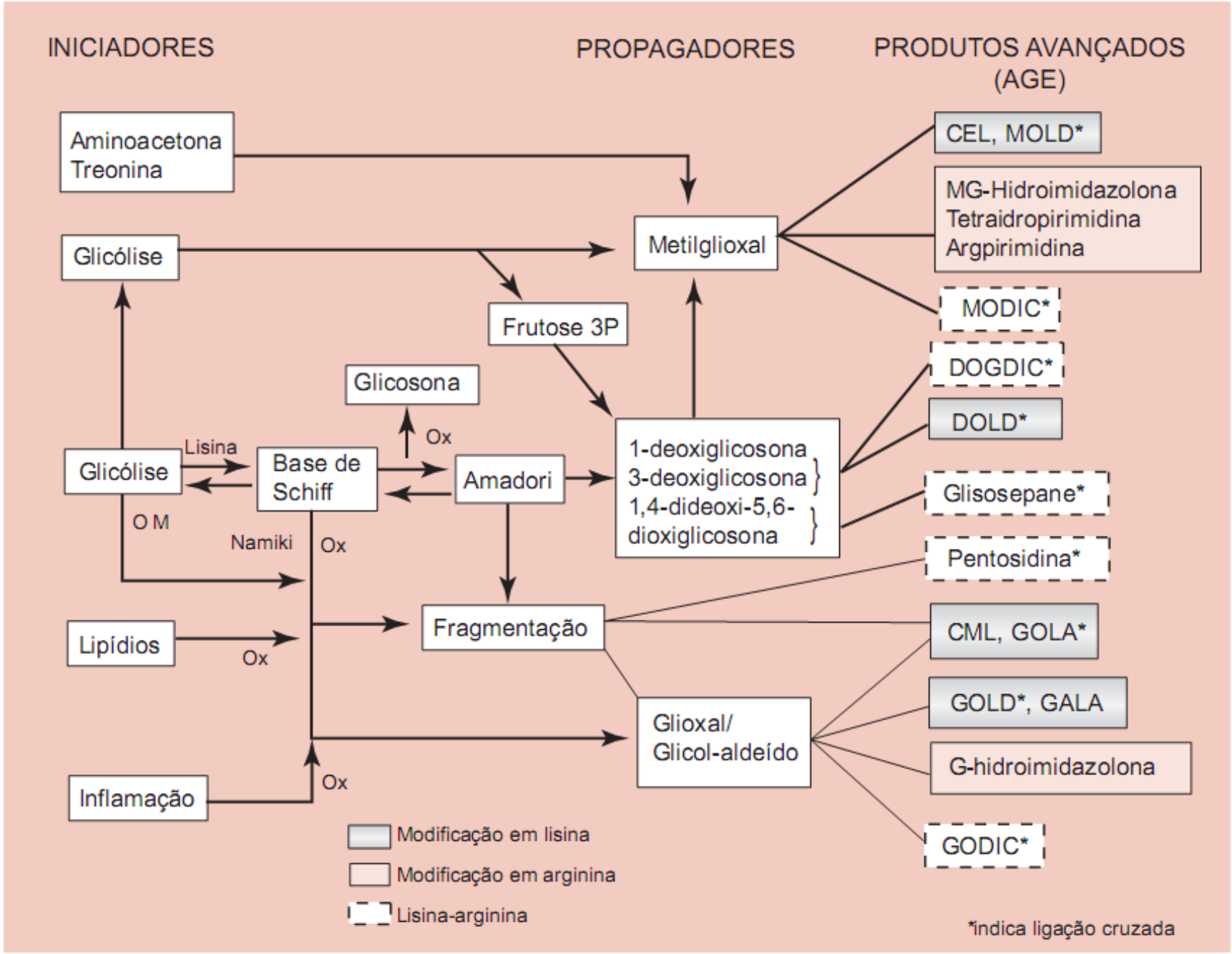
INICIADORES
PROPAGADORES
PRODUTOS AVANÇADOS (AGE)
Aminoacetona
Treonina
Glicólise
Metilglioxal
Frutose 3P
Glicosona
Ox
Glicólise
Lisina
Base de Schiff
Amadori
1-deoxiglicosona
3-deoxiglicosona
1,4-dideoxi-5,6-dioxiglicosona
O M
Namiki
Ox
Lipídios
Ox
Fragmentação
Glioxal/ Glicol-aldeído
Inflamação
Ox
CEL, MOLD*
MG-Hidroimidazolona
Tetraidropirimidina
Argpirimidina
MODIC*
DOGDIC*
DOLD*
Glisosepane*
Pentosidina*
CML, GOLA*
GOLD*, GALA
G-hidroimidazolona
GODIC*
Modificação em lisina
Modificação em arginina
Lisina-arginina
*indica ligação cruzada

AGES

- Altera estrutura do colágeno e outras proteínas

- Interagem com RAGEs (receptores) – rim: podócito >> Modulação celular

JAK/STAT – NF-kB > Mitose

Via Smad > Células mesangiais > citocinas fibrogênicas, TGF-B e PDGF > produção de colágeno IV, laminina, fibronectina...)

- Demonstração de pentosidina (AGEs) – Nódulos mesangiais e zonas de fibrose intersticial em ND e IGN.

Diabetes *Mellitus* tipo I e tipo II
Histopatologia Semelhante

Aumento da matriz extracelular:

- Colágenos IV e VI,
- Lamina
- Fibronectina

Aumento da produção e/ou diminuição da degradação

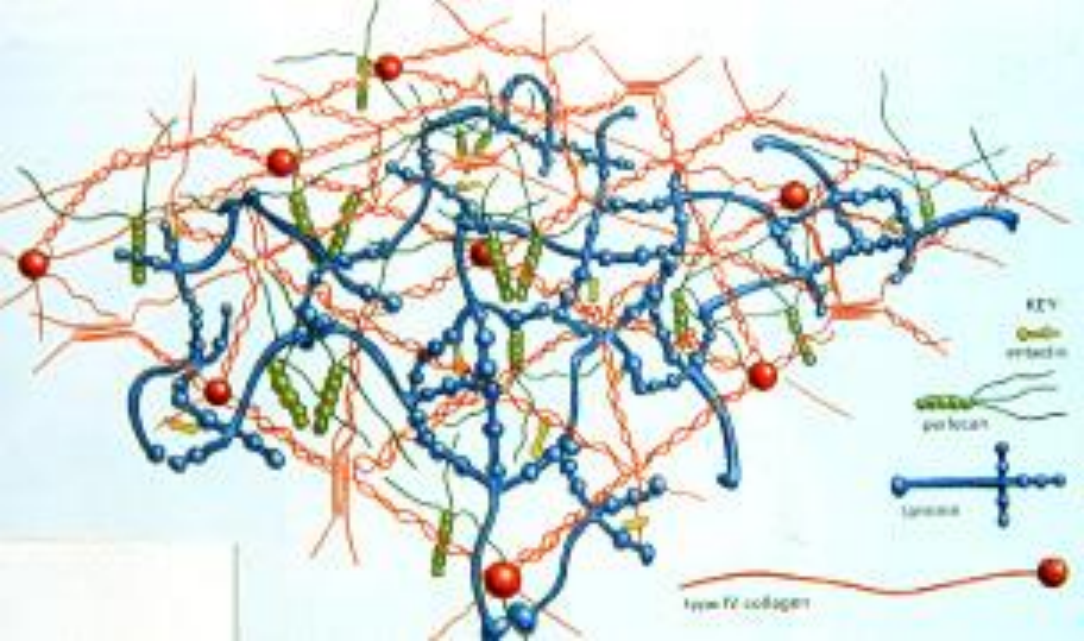
KEY
entactin
perlecan
laminin
type IV collagen

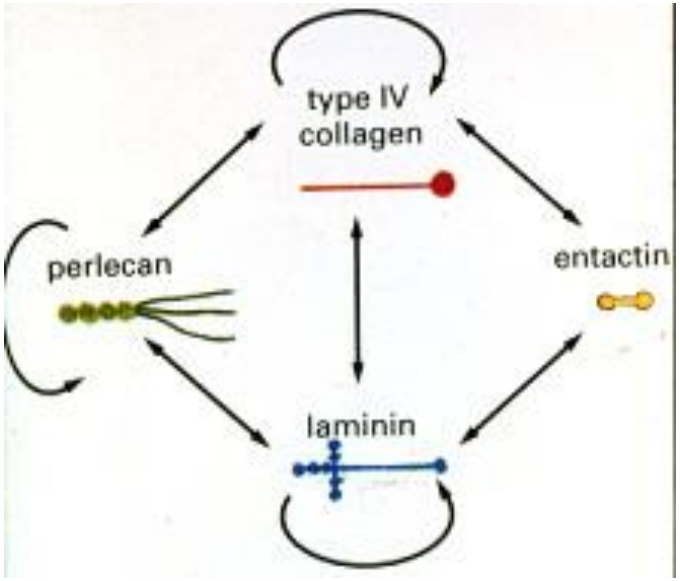
type IV
collagen
perlecan
entactin
laminin

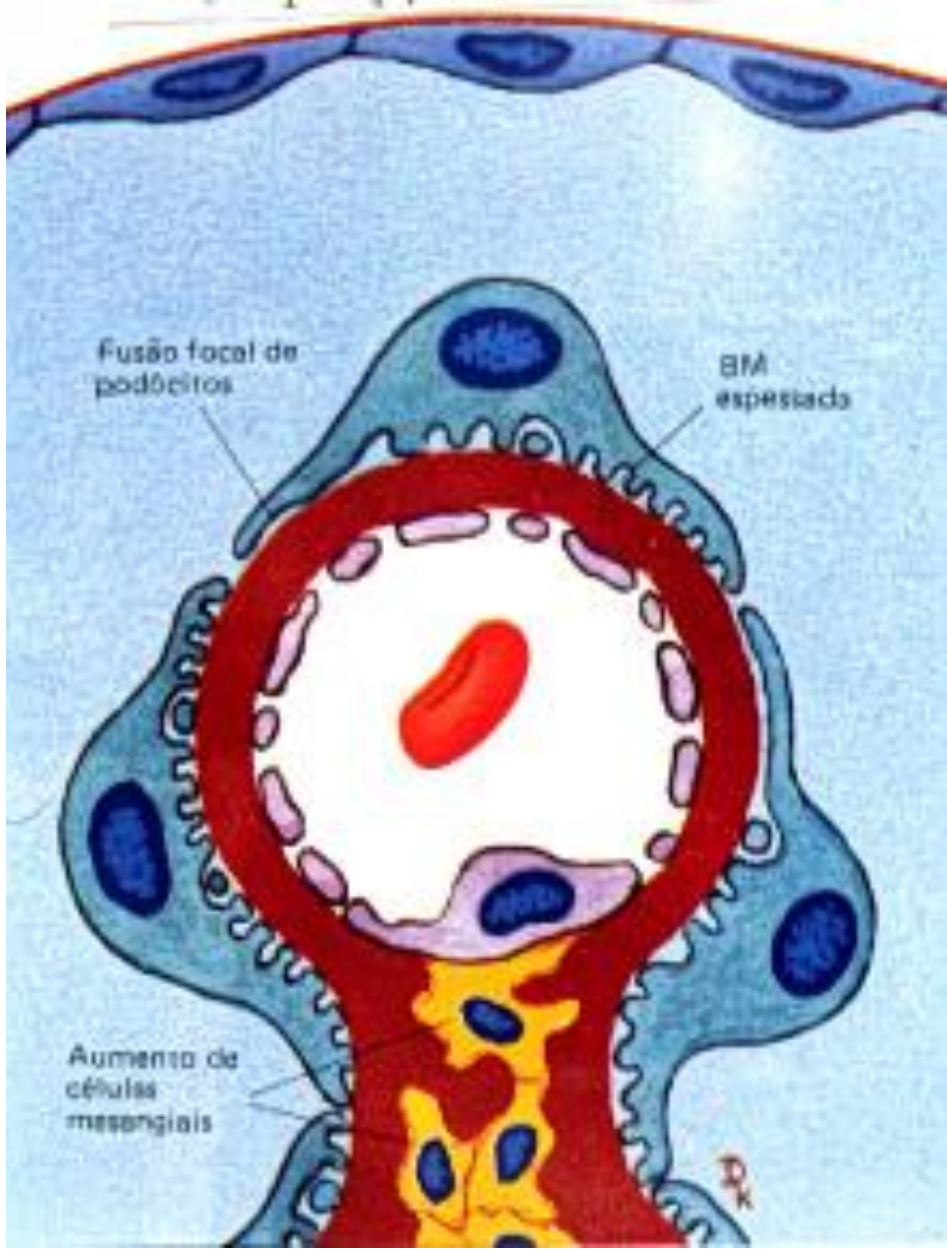
Fusão focal de
podócitos
BM
espessada
Aumento de
células
mesangiais

Diabetes Mellitus

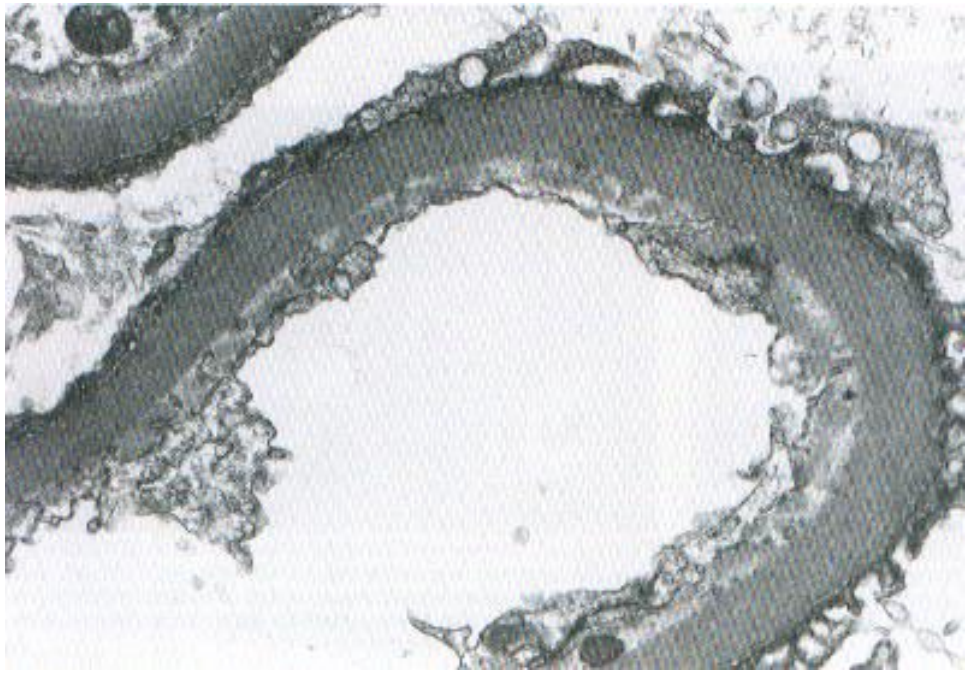

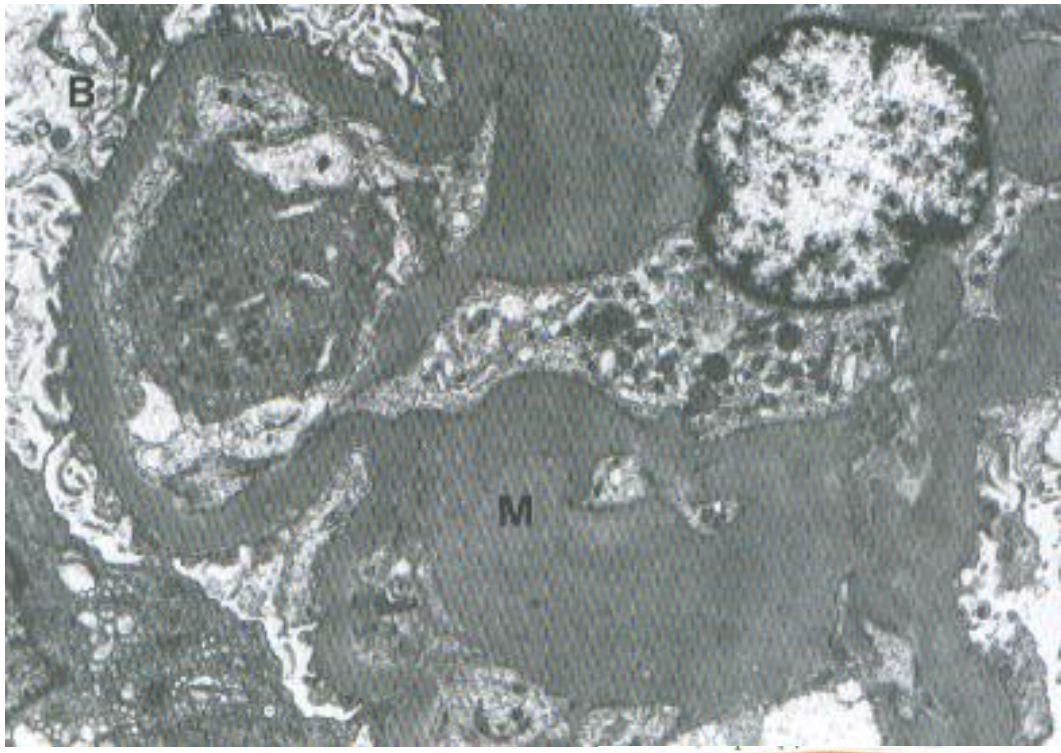

- Aumento Mesângio

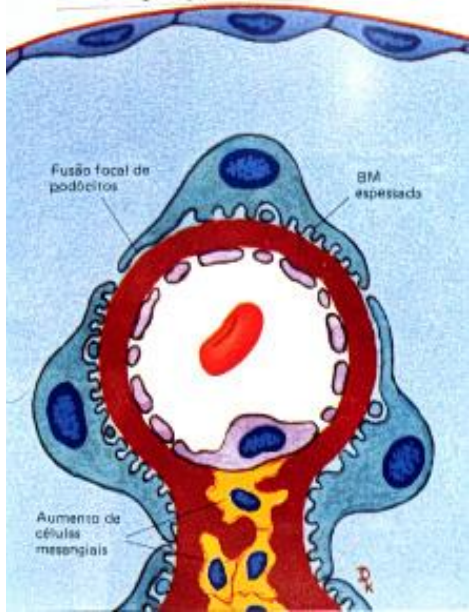

MBG = 300 a 400nm normal

(mulher-395nm; homem-430nm)

Diabetes: 1,5 a 2,5 anos - aumento da espessura

- fases iniciais=1200nm.
- avançado: 3000 a 4000nm

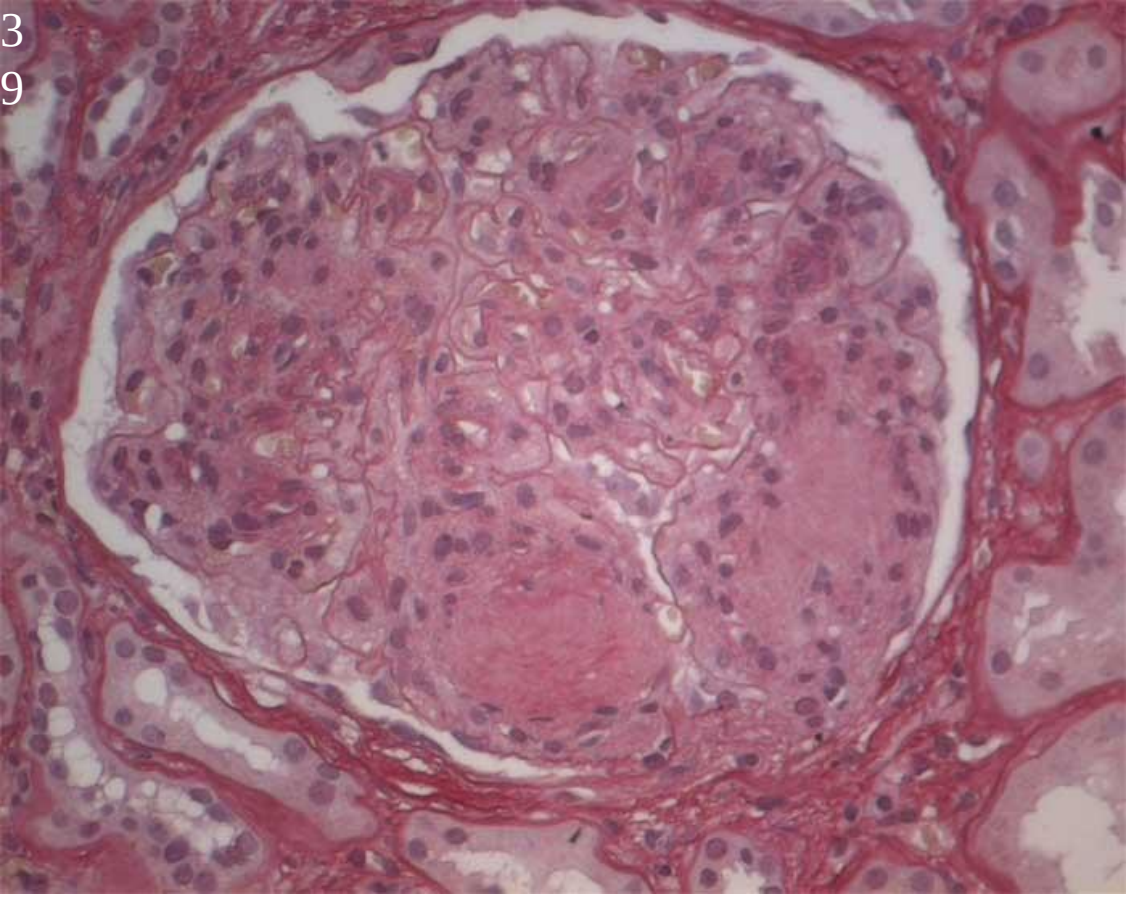

BR110660_PS, 20x2,0

PAS +

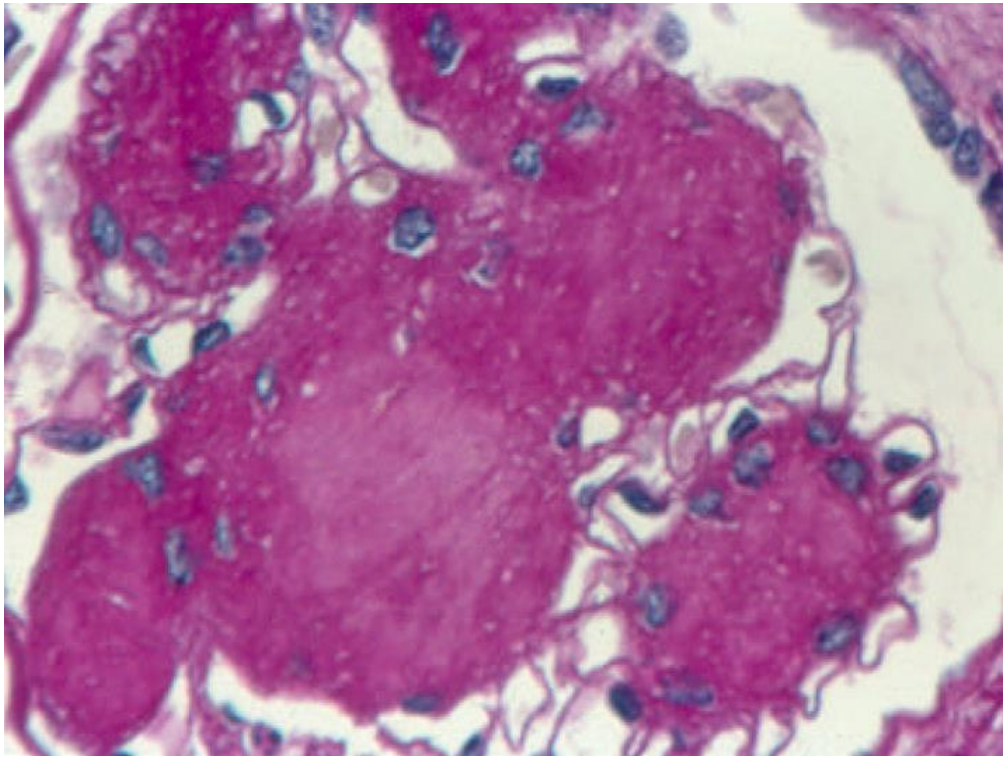

Fioretto & Mauer, 2007

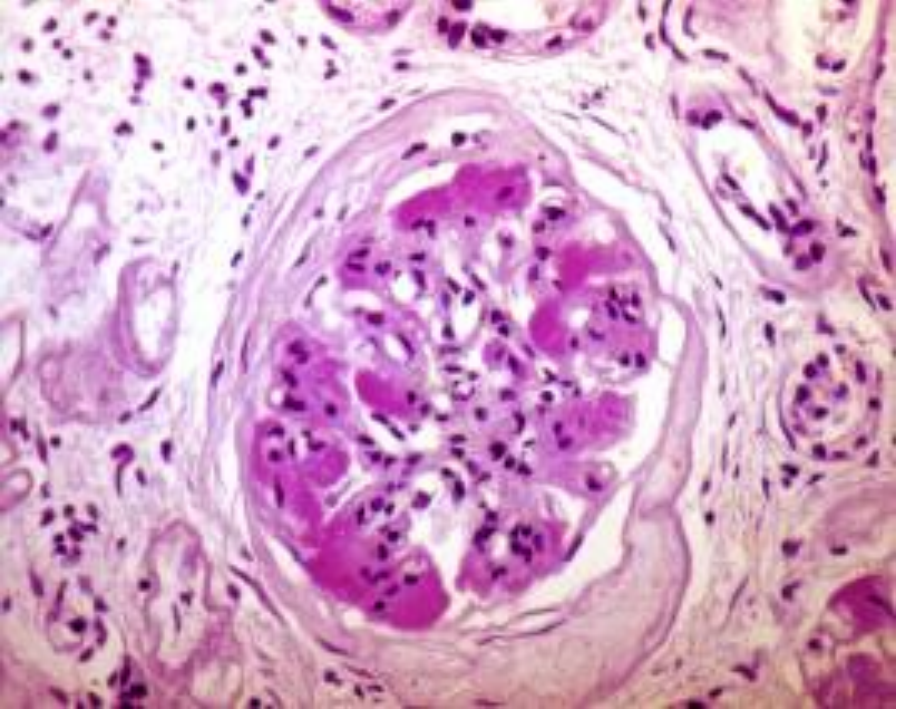

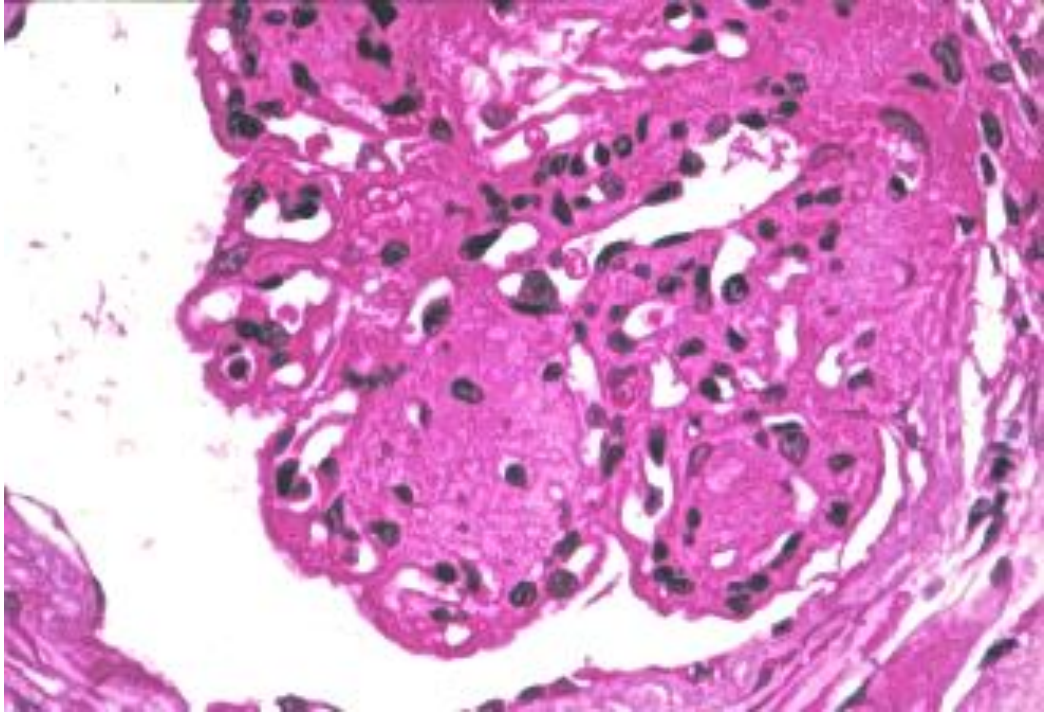

Glomeruloesclerose intercapilar difusa

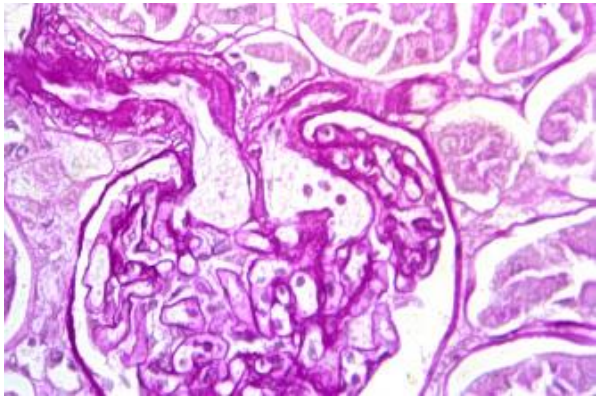

Glomeruloesclerose intercapilar nodular

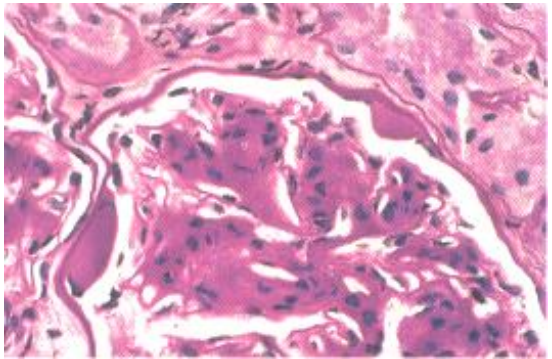

Imunofluorescência Direta

IF:10 glom

- IgA
- IgG
- IgM
- *Kappa*
- *Lambda*
- Fibrinogen
- C1q
- C3

IF

- Afastar outras entidades
- Doenças sobrepostas

ME

- Diagnóstico ND classe I
- Afastar outras entidades
- Doenças sobrepostas

Pathologic Classification of Diabetic Nephropathy

Thijs W. Cohen Tervaert,* Antien L. Mooyaart,* Kerstin Amann,† Arthur H. Cohen,‡ H. Terence Cook,§ Cinthia B. Drachenberg,‖ Franco Ferrario,¶ Agnes B. Fogo,** Mark Haas,‡ Emile de Heer,* Kensuke Joh,†† Laure H. Noël,‡‡ Jai Radhakrishnan,§§ Surya V. Seshan,‖‖ Ingeborg M. Bajema,* and Jan A. Bruijn,* on behalf of the Renal Pathology Society

Sociedade Patologia Renal

J Am Soc Nephrol 21: 556–563, 2010.

Table 1. Glomerular classification of DN

Class	Description	Inclusion Criteria
I	Mild or nonspecific LM changes and EM-proven GBM thickening	Biopsy does not meet any of the criteria mentioned below for class II, III, or IV GBM > 395 nm in female and >430 nm in male individuals 9 years of age and older[a]
IIa	Mild mesangial expansion	Biopsy does not meet criteria for class III or IV Mild mesangial expansion in >25% of the observed mesangium
IIb	Severe mesangial expansion	Biopsy does not meet criteria for class III or IV Severe mesangial expansion in >25% of the observed mesangium
III	Nodular sclerosis (Kimmelstiel–Wilson lesion)	Biopsy does not meet criteria for class IV At least one convincing Kimmelstiel–Wilson lesion
IV	Advanced diabetic glomerulosclerosis	Global glomerular sclerosis in >50% of glomeruli Lesions from classes I through III

Tervaert TWC et al, 2010

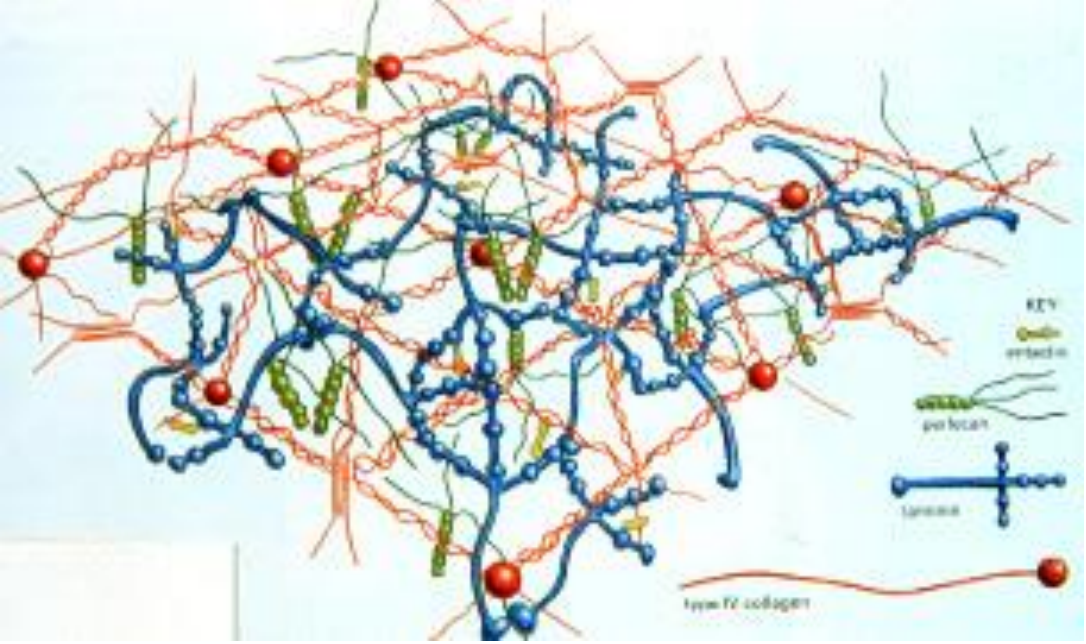
KEY
entactin
perlecan
laminin
type IV collagen

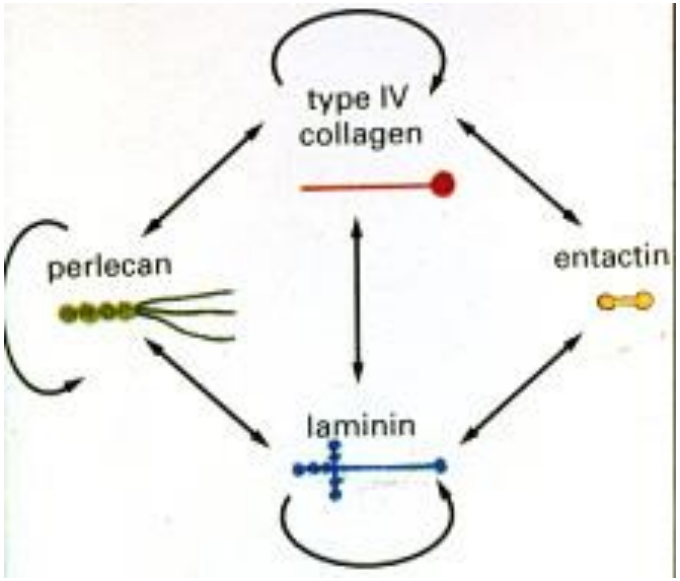
type IV
collagen
perlecan
entactin
laminin

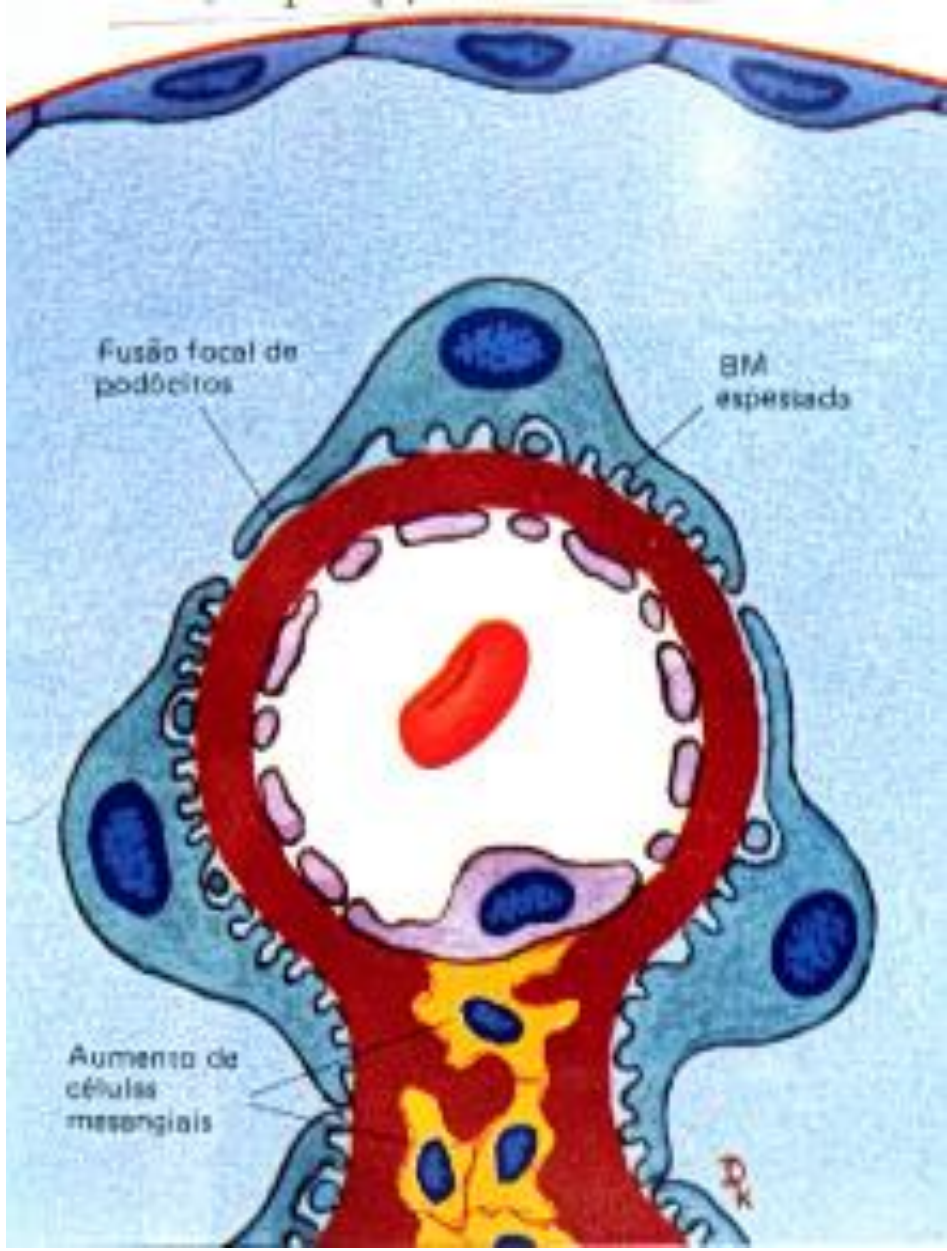
Fusão focal de
podócitos
BM
espessada
Aumento de
células
mesangiais

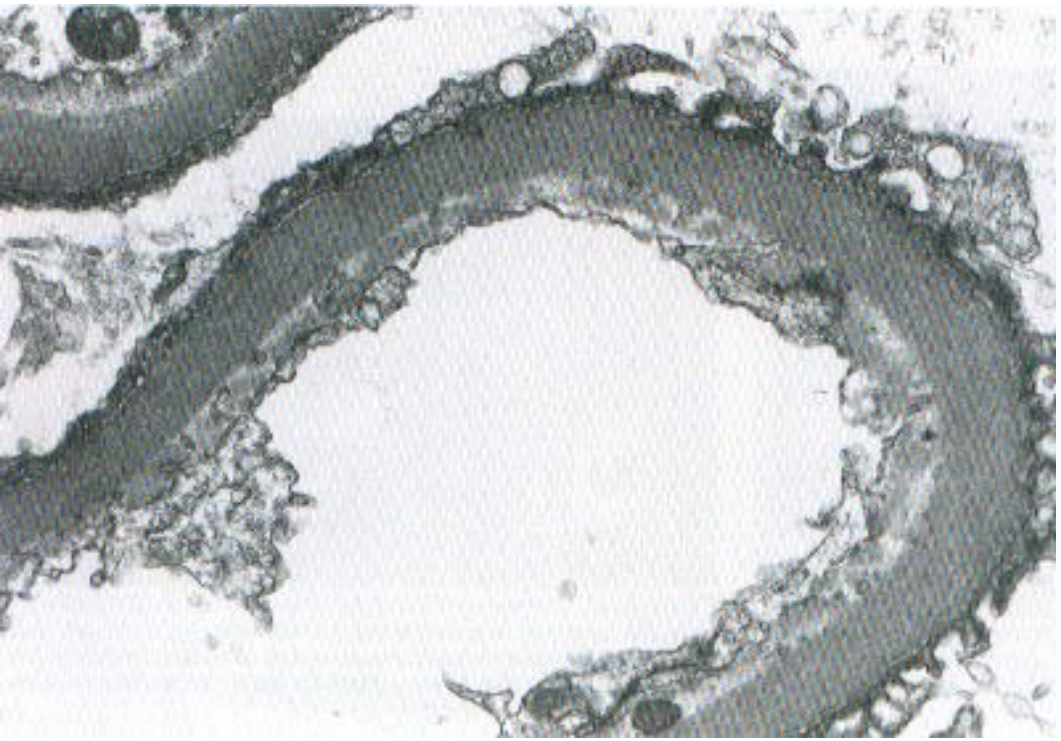

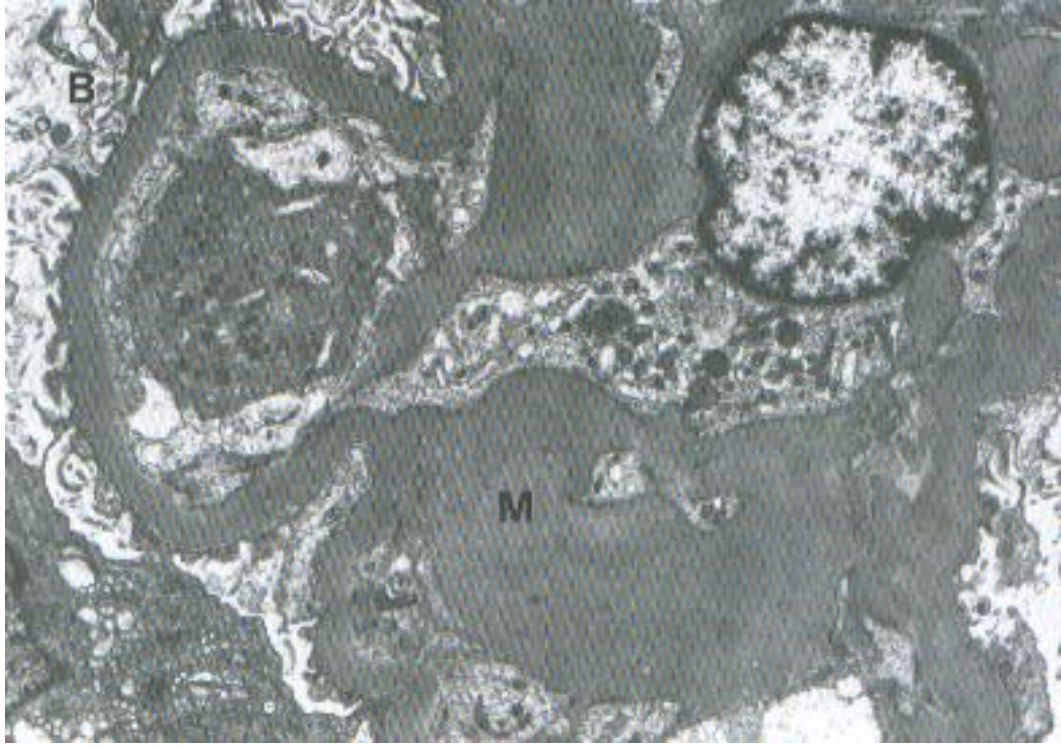

- mesângio
aumento dos eixos com poucas células

MBG = 300 a 400nm normal
(mulher-395nm; homem-430nm)
Diabetes: 1,5 a 2,5 anos - aumento da espessura
- fases iniciais=1200nm.
- avançado: 3000 a 4000nm
- frouxo, áspero ou delicado, às vezes fibrilar, lamelado

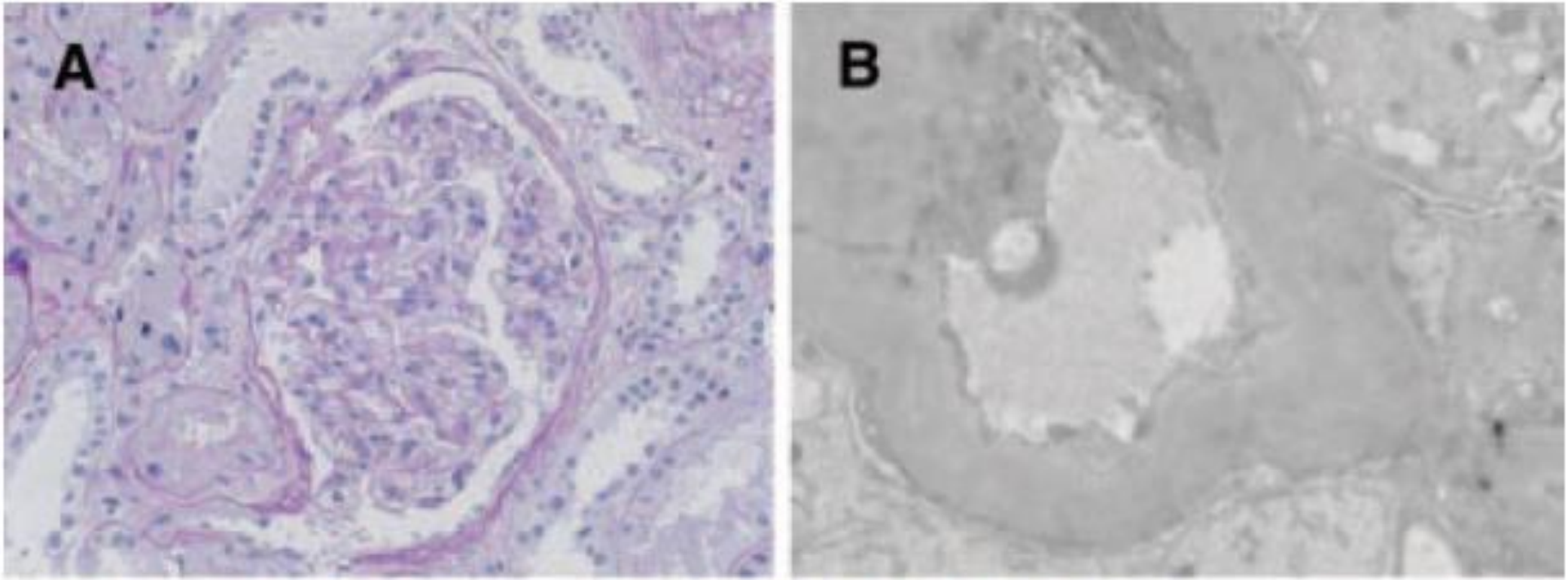

MBG = 671nm

Tervaert TWC et al, 2010

Table 1. Glomerular classification of DN

Class	Description	Inclusion Criteria
I	Mild or nonspecific LM changes and EM-proven GBM thickening	Biopsy does not meet any of the criteria mentioned below for class II, III, or IV GBM > 395 nm in female and >430 nm in male individuals 9 years of age and older[a]
IIa	Mild mesangial expansion	Biopsy does not meet criteria for class III or IV Mild mesangial expansion in >25% of the observed mesangium
IIb	Severe mesangial expansion	Biopsy does not meet criteria for class III or IV Severe mesangial expansion in >25% of the observed mesangium
III	Nodular sclerosis (Kimmelstiel–Wilson lesion)	Biopsy does not meet criteria for class IV At least one convincing Kimmelstiel–Wilson lesion
IV	Advanced diabetic glomerulosclerosis	Global glomerular sclerosis in >50% of glomeruli Lesions from classes I through III

Tervaert TWC et al, 2010

Table 1. Glomerular classification of DN

Class	Description	Inclusion Criteria
I	Mild or nonspecific LM changes and EM-proven GBM thickening	Biopsy does not meet any of the criteria mentioned below for class II, III, or IV GBM > 395 nm in female and >430 nm in male individuals 9 years of age and older[a]
IIa	Mild mesangial expansion	Biopsy does not meet criteria for class III or IV Mild mesangial expansion in >25% of the observed mesangium
IIb	Severe mesangial expansion	Biopsy does not meet criteria for class III or IV Severe mesangial expansion in >25% of the observed mesangium
III	Nodular sclerosis (Kimmelstiel–Wilson lesion)	Biopsy does not meet criteria for class IV At least one convincing Kimmelstiel–Wilson lesion
IV	Advanced diabetic glomerulosclerosis	Global glomerular sclerosis in >50% of glomeruli Lesions from classes I through III

Tervaert TWC et al, 2010

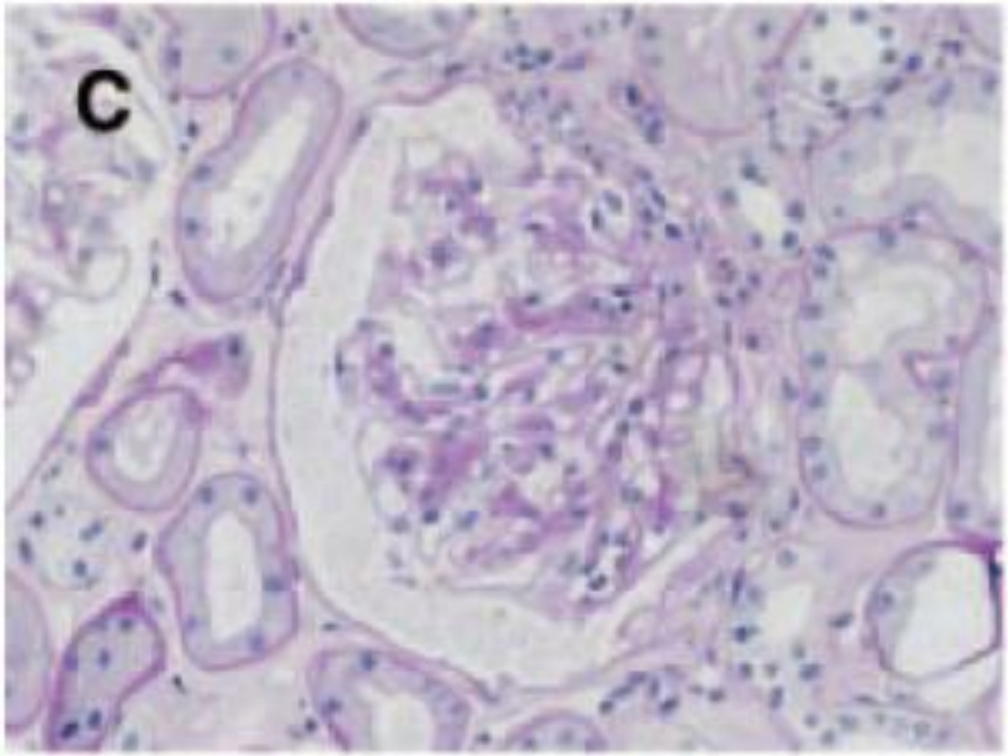

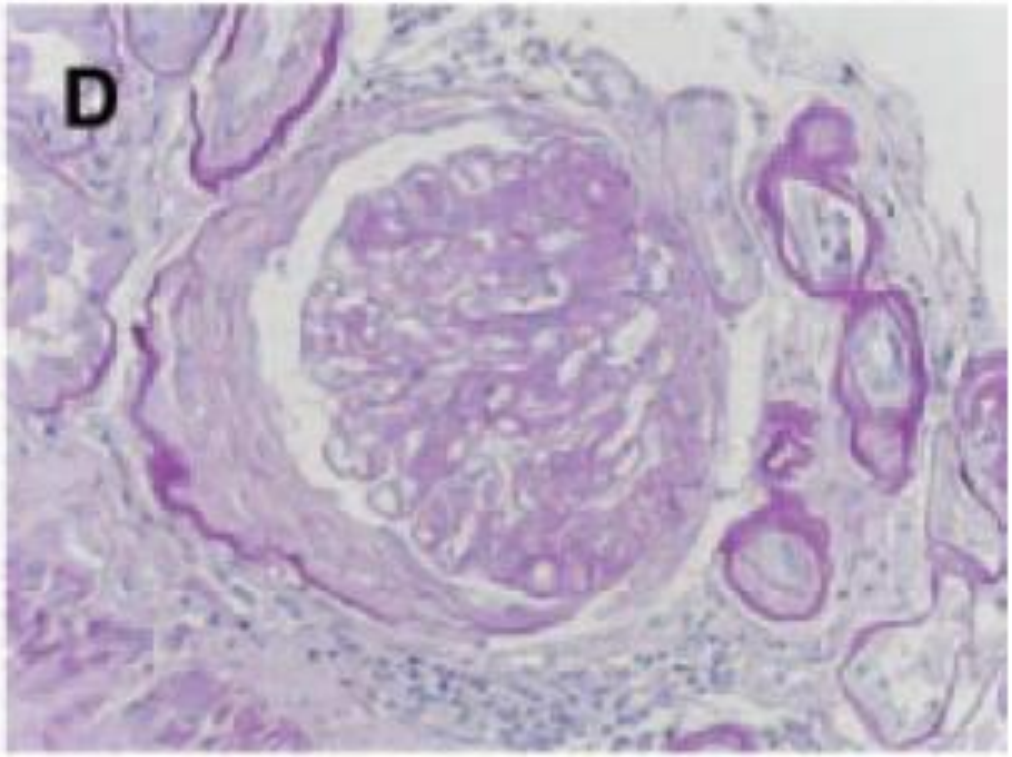

IIa

IIb

Tervaert TWC et al, 2010

Table 1. Glomerular classification of DN

Class	Description	Inclusion Criteria
I	Mild or nonspecific LM changes and EM-proven GBM thickening	Biopsy does not meet any of the criteria mentioned below for class II, III, or IV GBM > 395 nm in female and >430 nm in male individuals 9 years of age and older[a]
IIa	Mild mesangial expansion	Biopsy does not meet criteria for class III or IV Mild mesangial expansion in >25% of the observed mesangium
IIb	Severe mesangial expansion	Biopsy does not meet criteria for class III or IV Severe mesangial expansion in >25% of the observed mesangium
III	Nodular sclerosis (Kimmelstiel–Wilson lesion)	Biopsy does not meet criteria for class IV At least one convincing Kimmelstiel–Wilson lesion
IV	Advanced diabetic glomerulosclerosis	Global glomerular sclerosis in >50% of glomeruli Lesions from classes I through III

Tervaert TWC et al, 2010

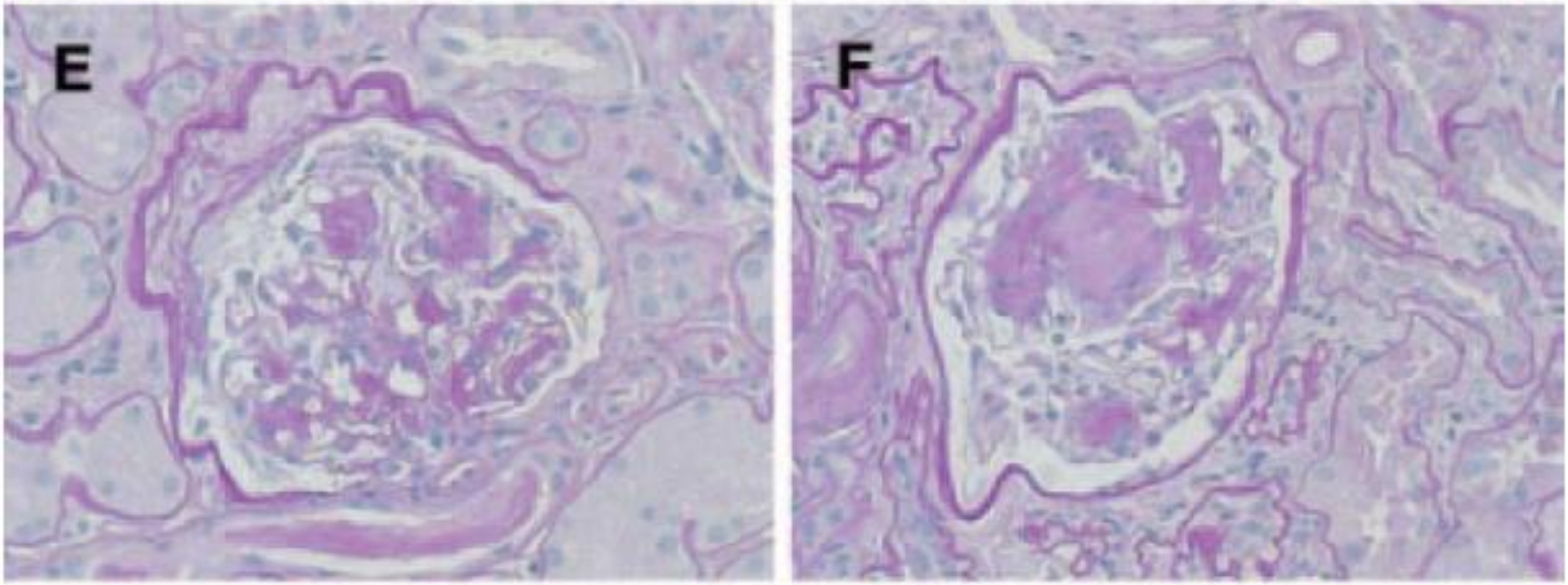

IIb III

Tervaert TWC et al, 2010

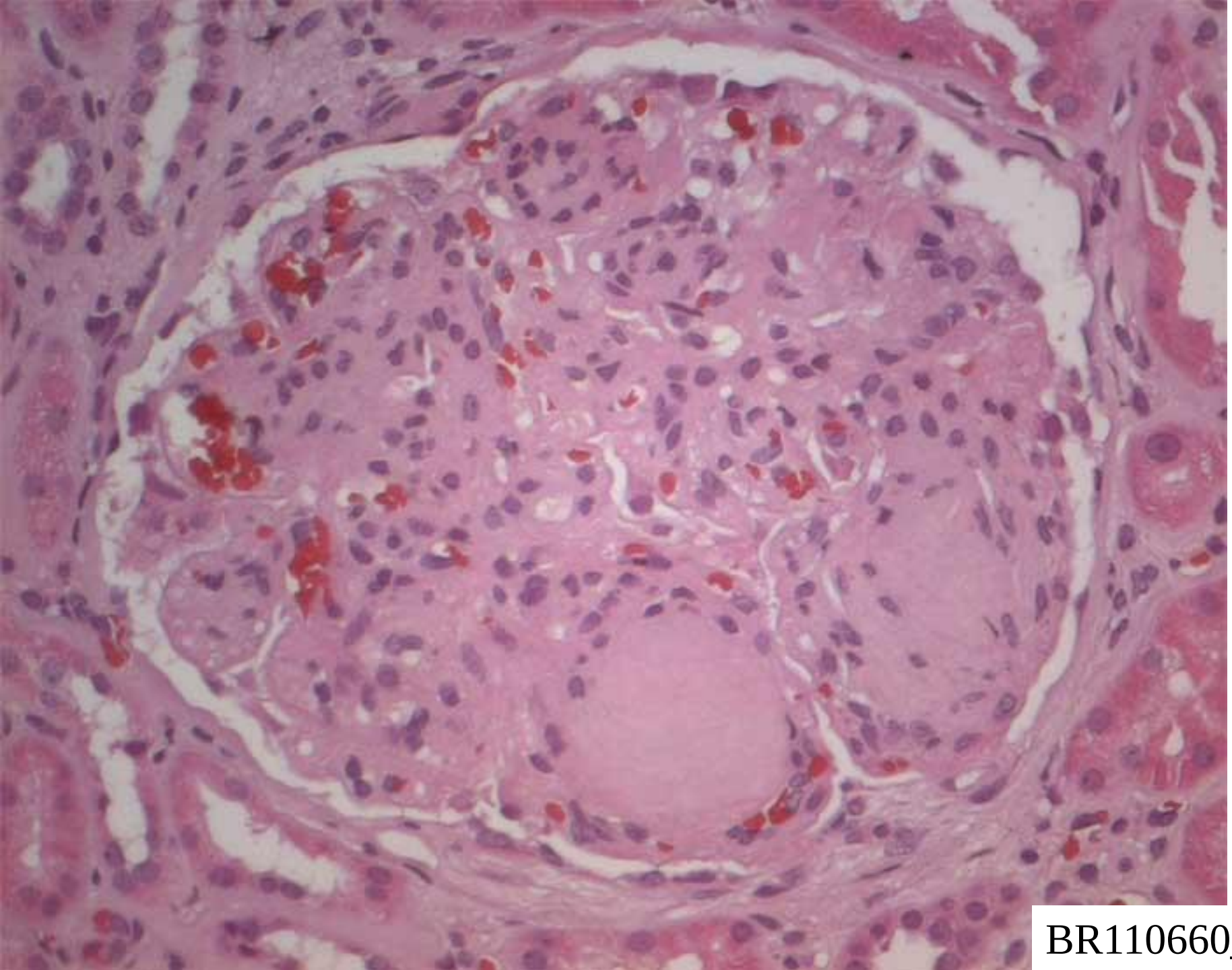

BR110660_HE, 20x2,0

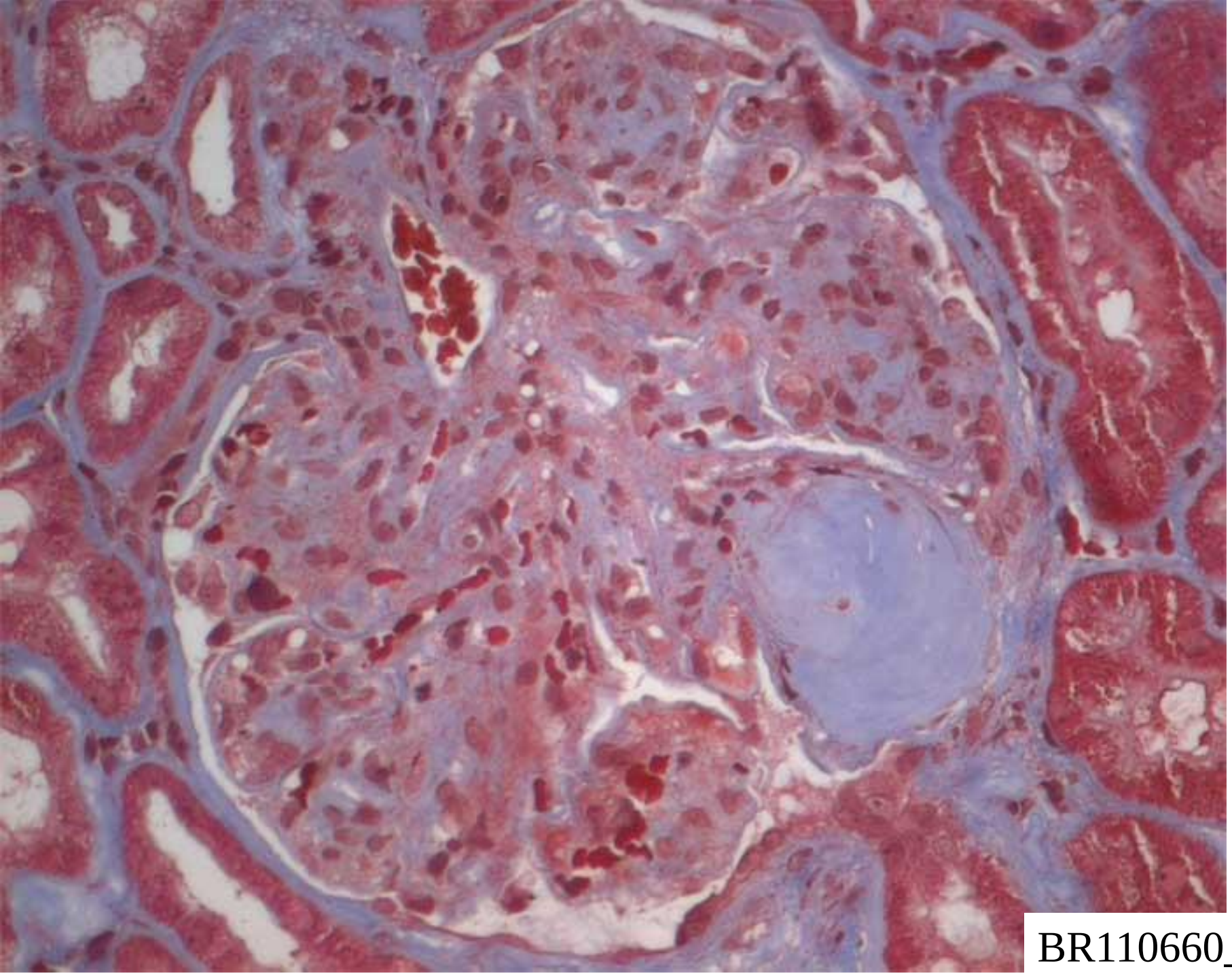

BR110660_TM, 20x2,0

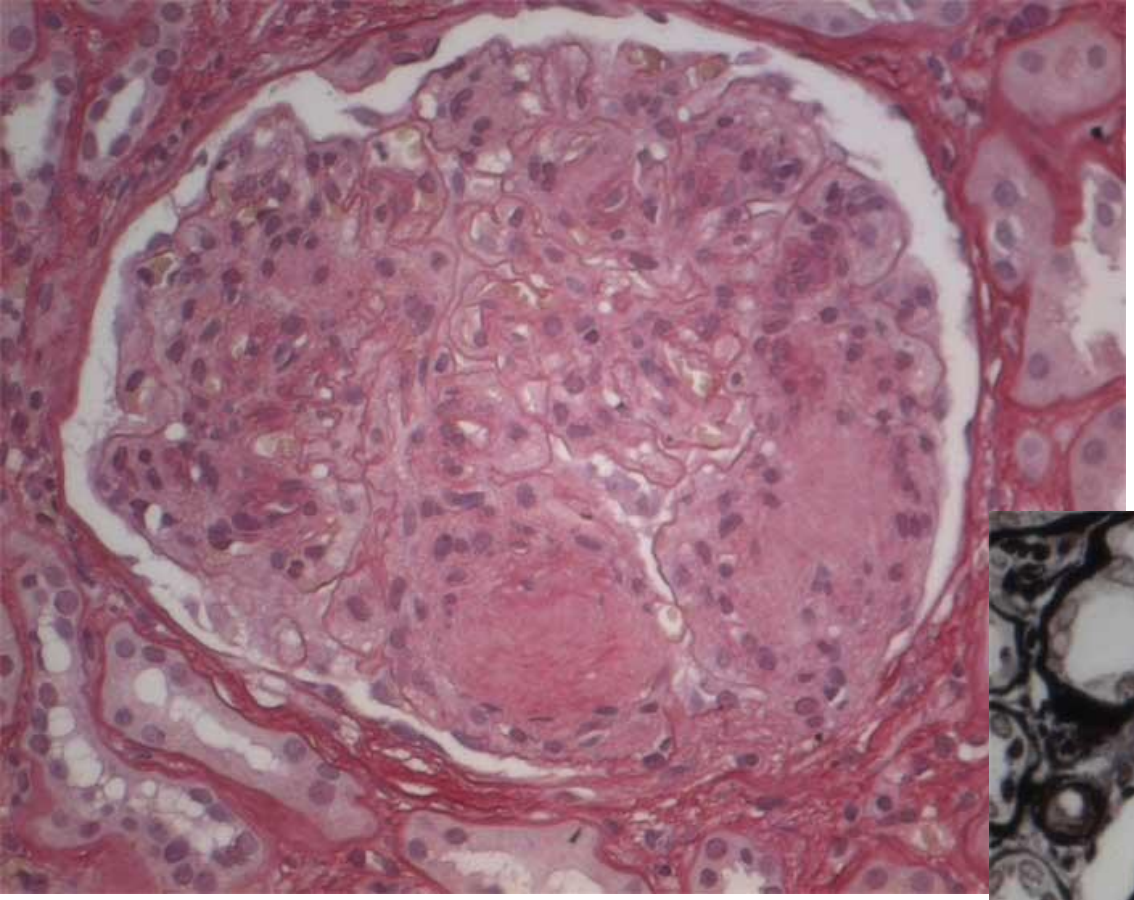

BR110660_PS, 20x2,0

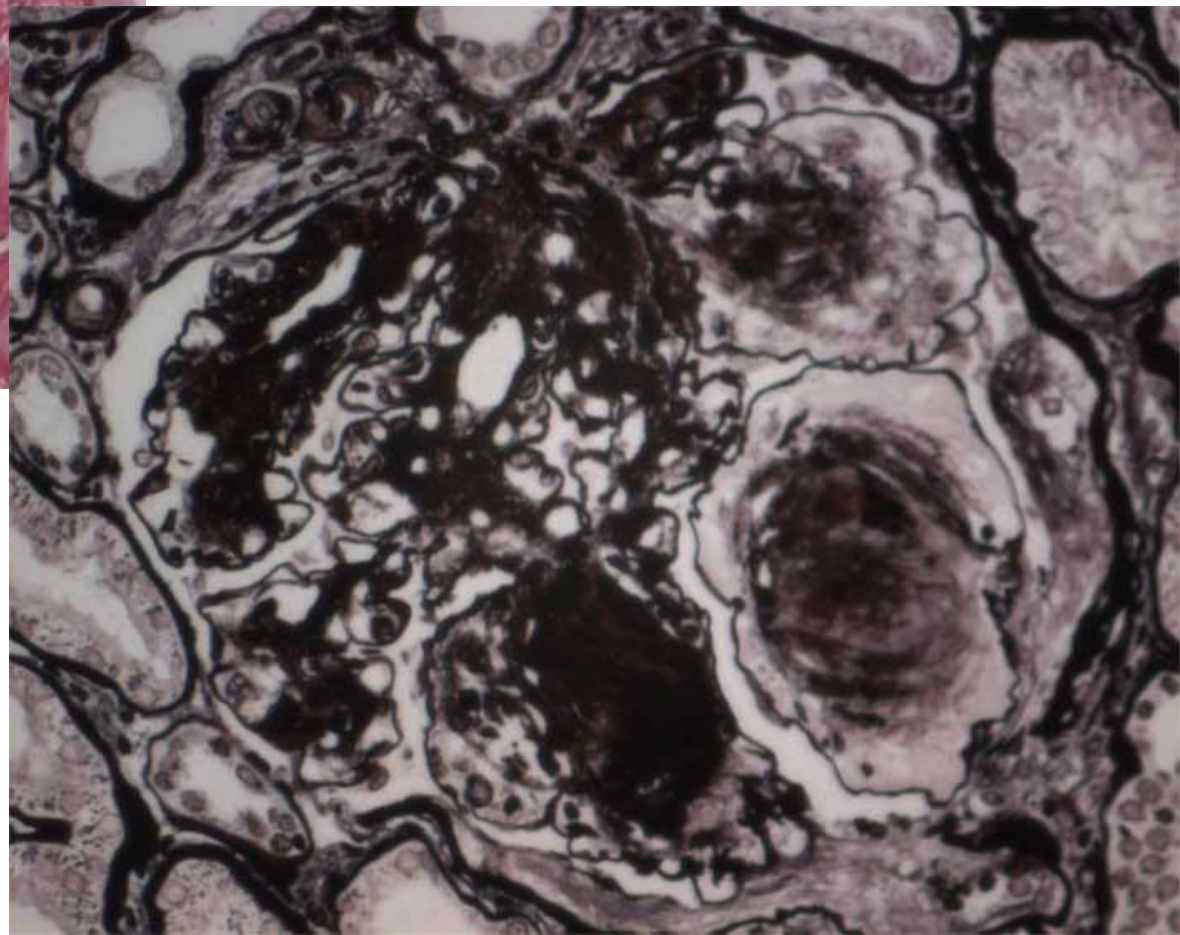

BR110660_PAMS, 20x2,0

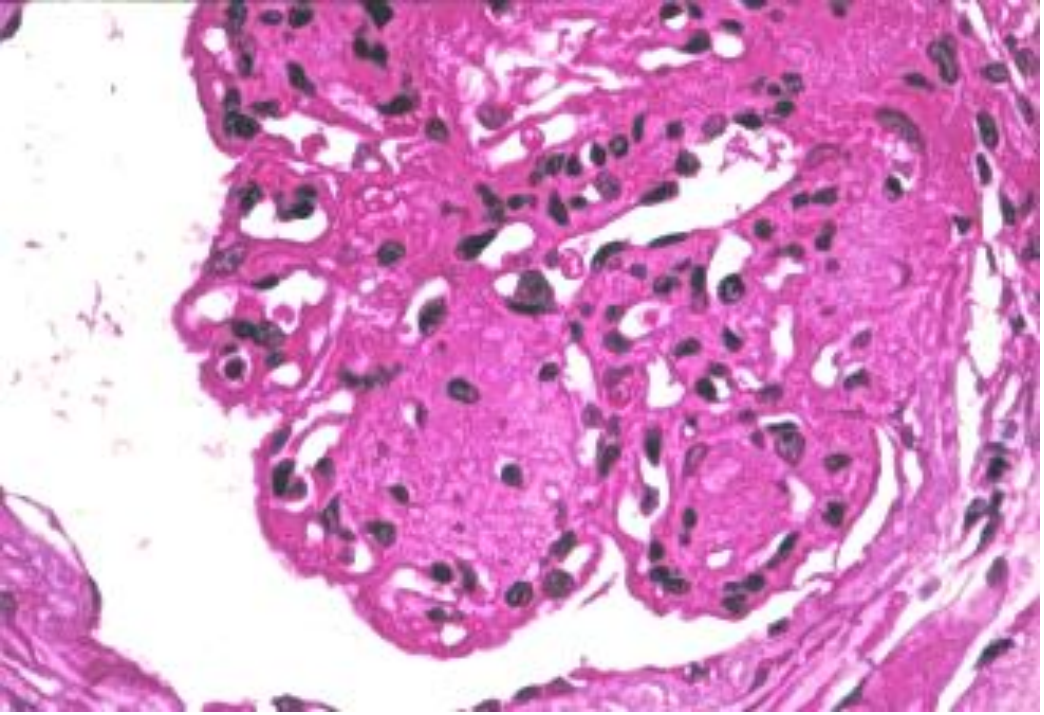

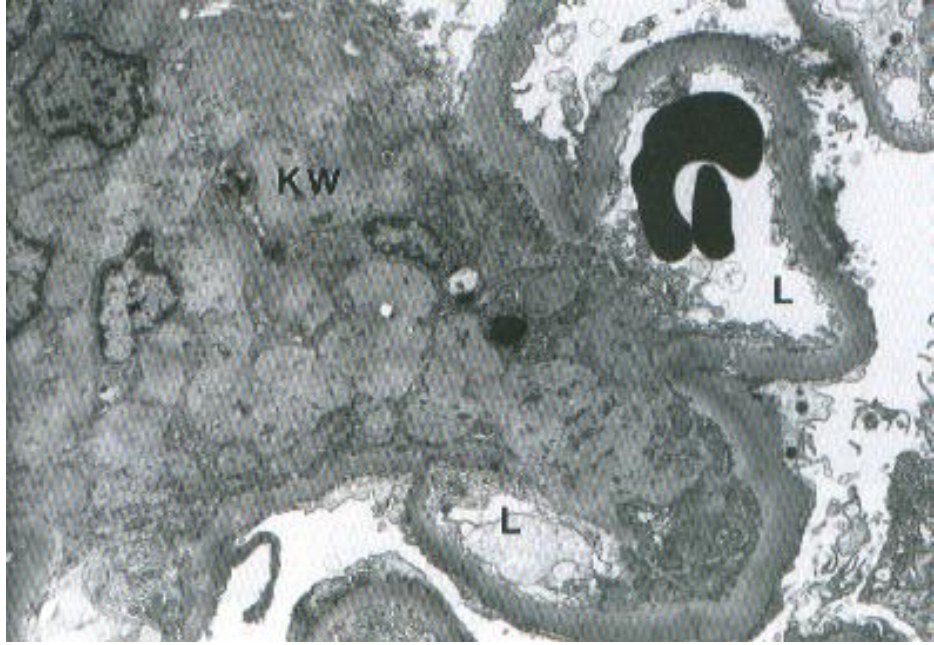

Kimmelstiel-Wilson
- nódulo hipocelular
- capilares periferia

PAS e prata positivos

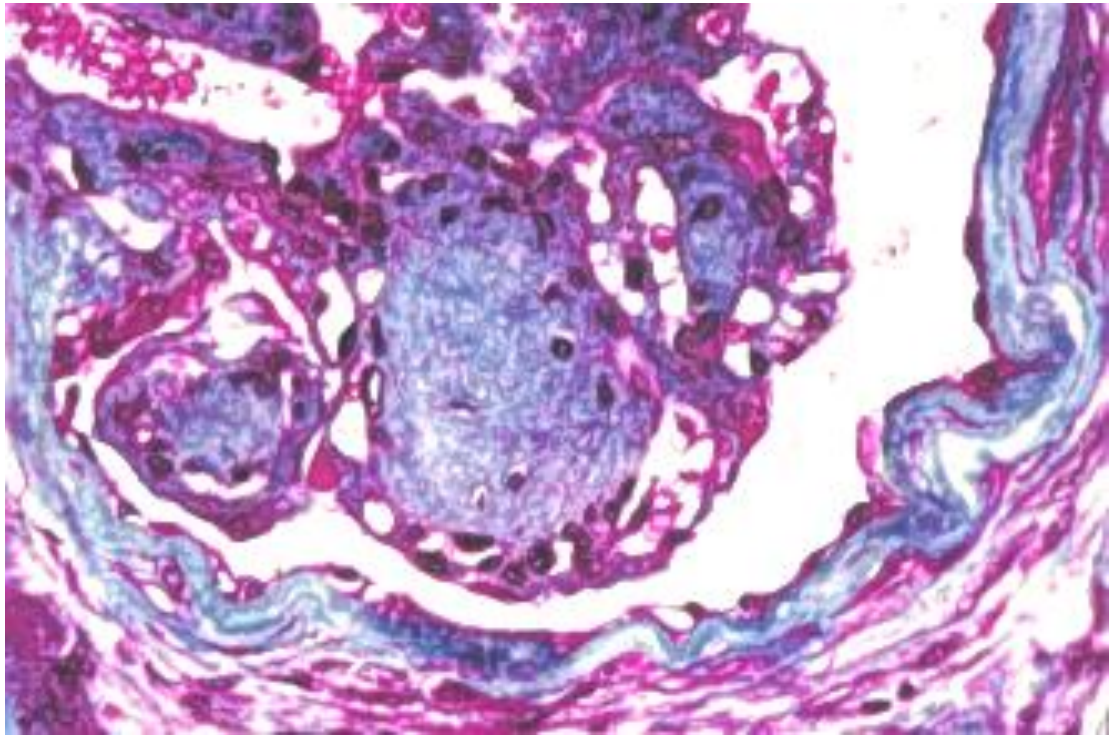

Table 1. Glomerular classification of DN

Class	Description	Inclusion Criteria
I	Mild or nonspecific LM changes and EM-proven GBM thickening	Biopsy does not meet any of the criteria mentioned below for class II, III, or IV GBM > 395 nm in female and >430 nm in male individuals 9 years of age and older[a]
IIa	Mild mesangial expansion	Biopsy does not meet criteria for class III or IV Mild mesangial expansion in >25% of the observed mesangium
IIb	Severe mesangial expansion	Biopsy does not meet criteria for class III or IV Severe mesangial expansion in >25% of the observed mesangium
III	Nodular sclerosis (Kimmelstiel–Wilson lesion)	Biopsy does not meet criteria for class IV At least one convincing Kimmelstiel–Wilson lesion
IV	Advanced diabetic glomerulosclerosis	Global glomerular sclerosis in >50% of glomeruli Lesions from classes I through III

Tervaert TWC et al, 2010

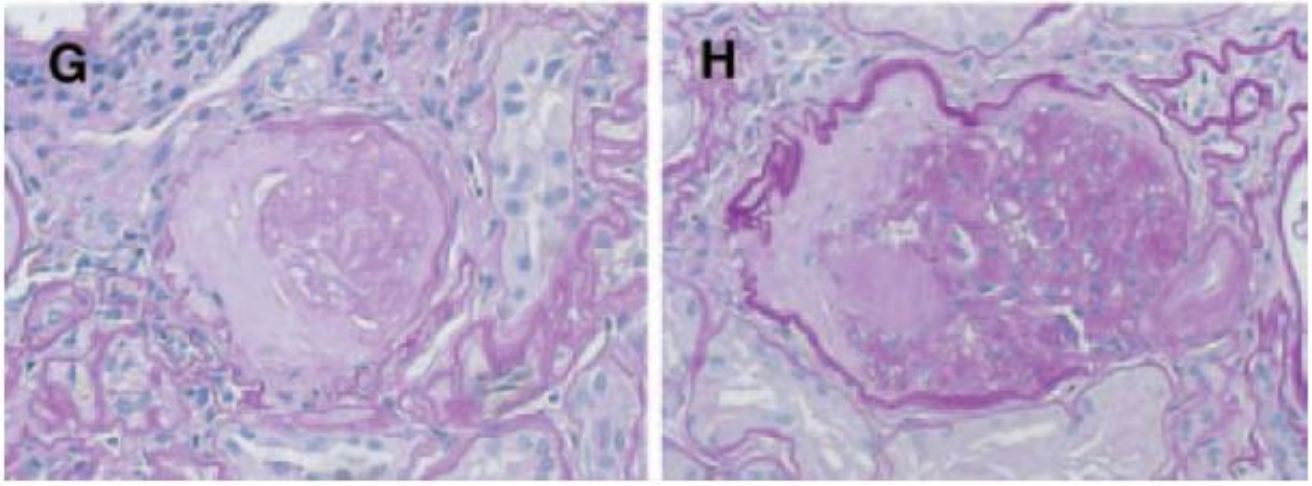

Tervaert TWC et al, 2010

IV
Esclerose glomerular > 50%
Histopatologia Diabetes
ou dados clínicos

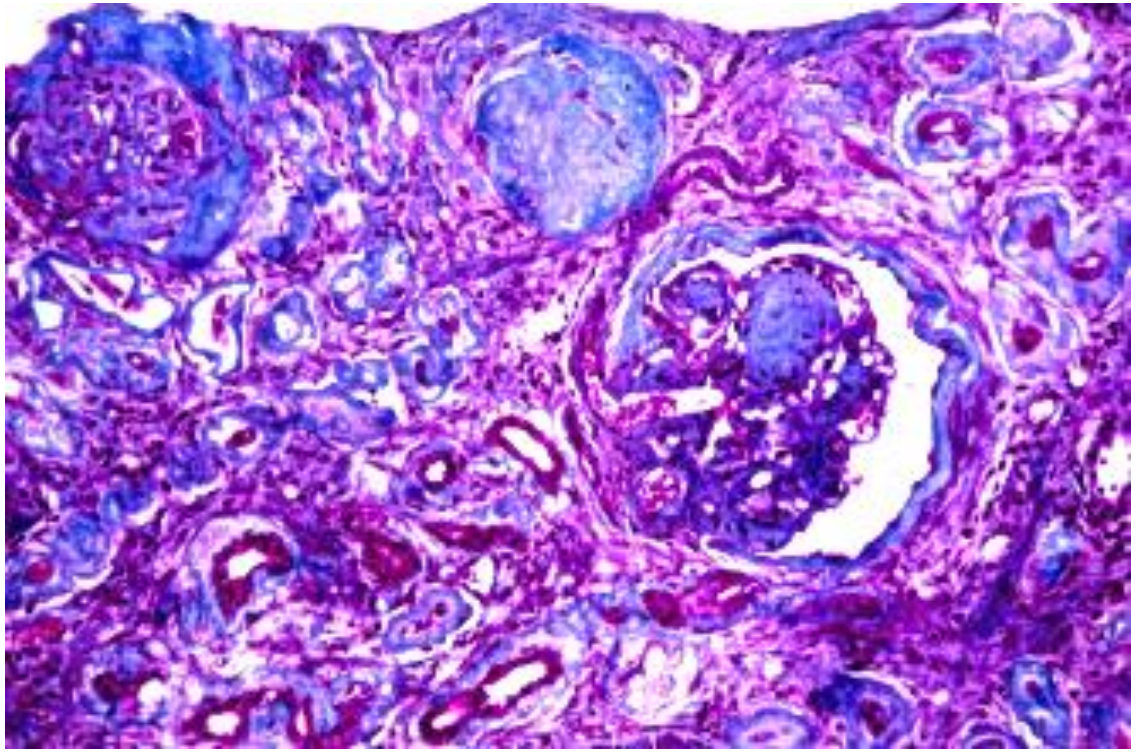

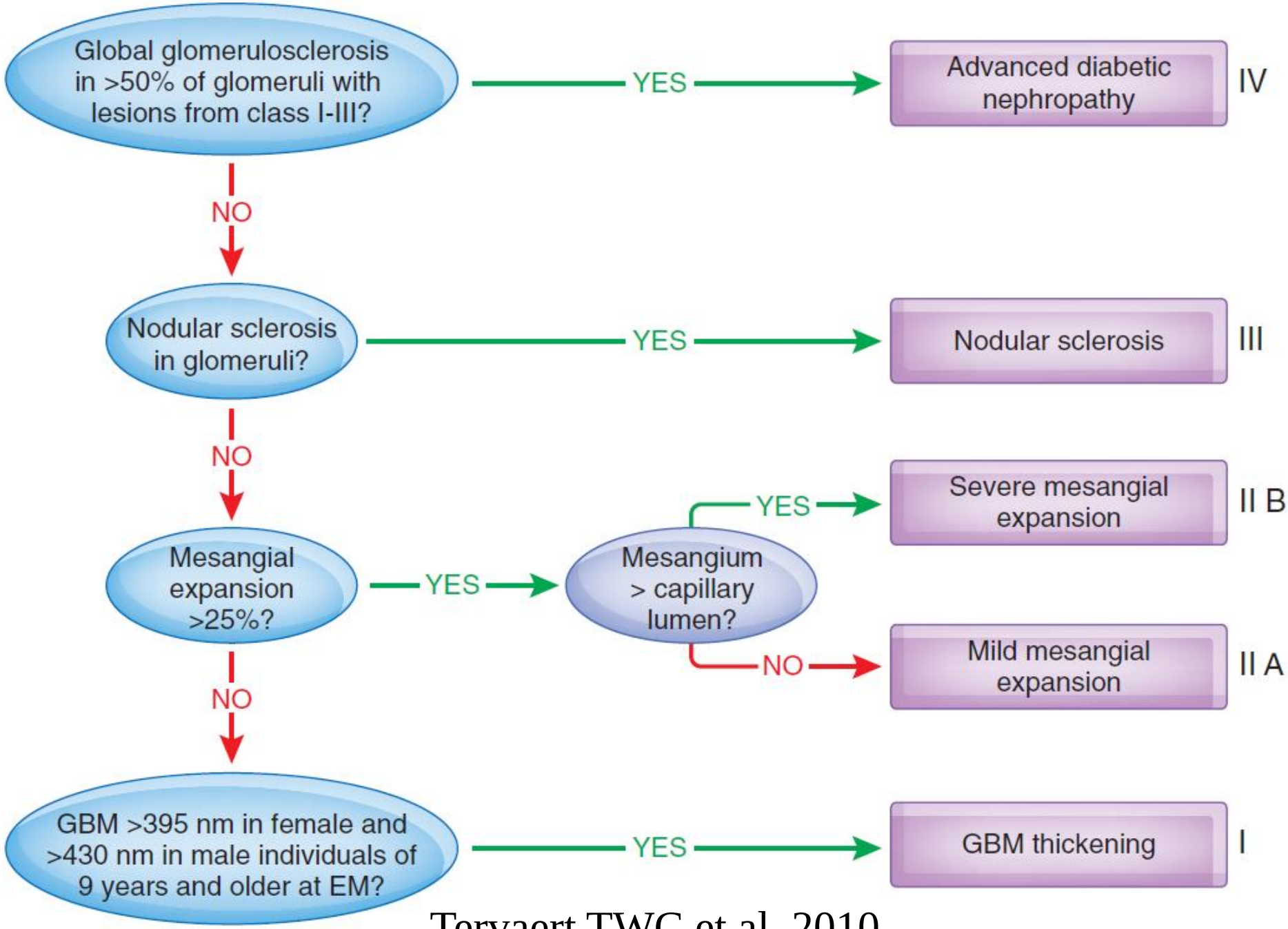

Tervaert TWC et al, 2010

Compartimentos

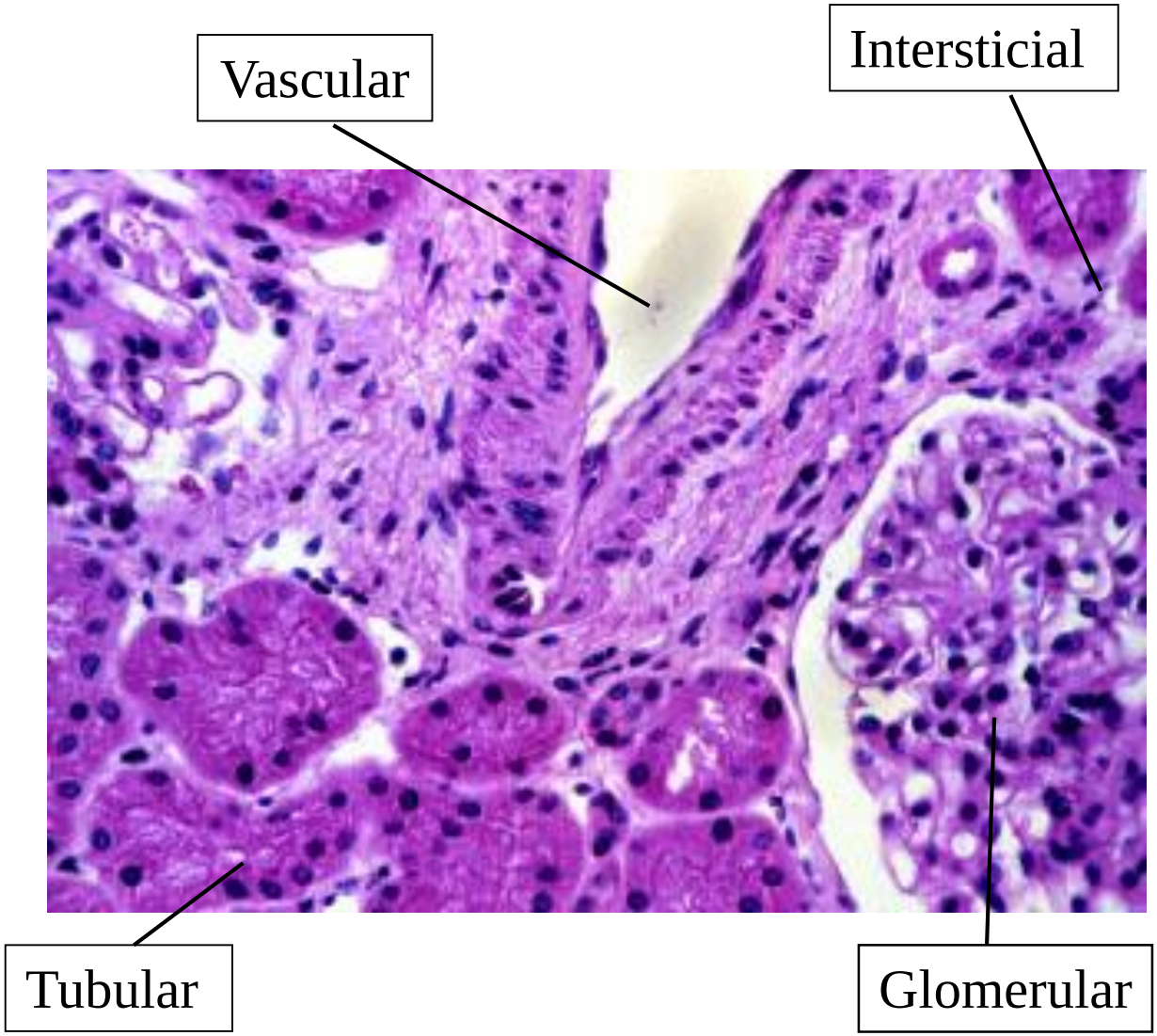

Table 2. Interstitial and vascular lesions of DN

Lesion	Criteria	Score
Interstitial lesions		
IFTA	No IFTA	0
	<25%	1
	25% to 50%	2
	>50%	3
interstitial inflammation	Absent	0
	Infiltration only in relation to IFTA	1
	Infiltration in areas without IFTA	2
Vascular lesions		
arteriolar hyalinosis	Absent	0
	At least one area of arteriolar hyalinosis	1
	More than one area of arteriolar hyalinosis	2
presence of large vessels	–	Yes/no
arteriosclerosis (score worst artery)	No intimal thickening	0
	Intimal thickening less than thickness of media	1
	Intimal thickening greater than thickness of media	2

Tervaert TWC et al, 2010

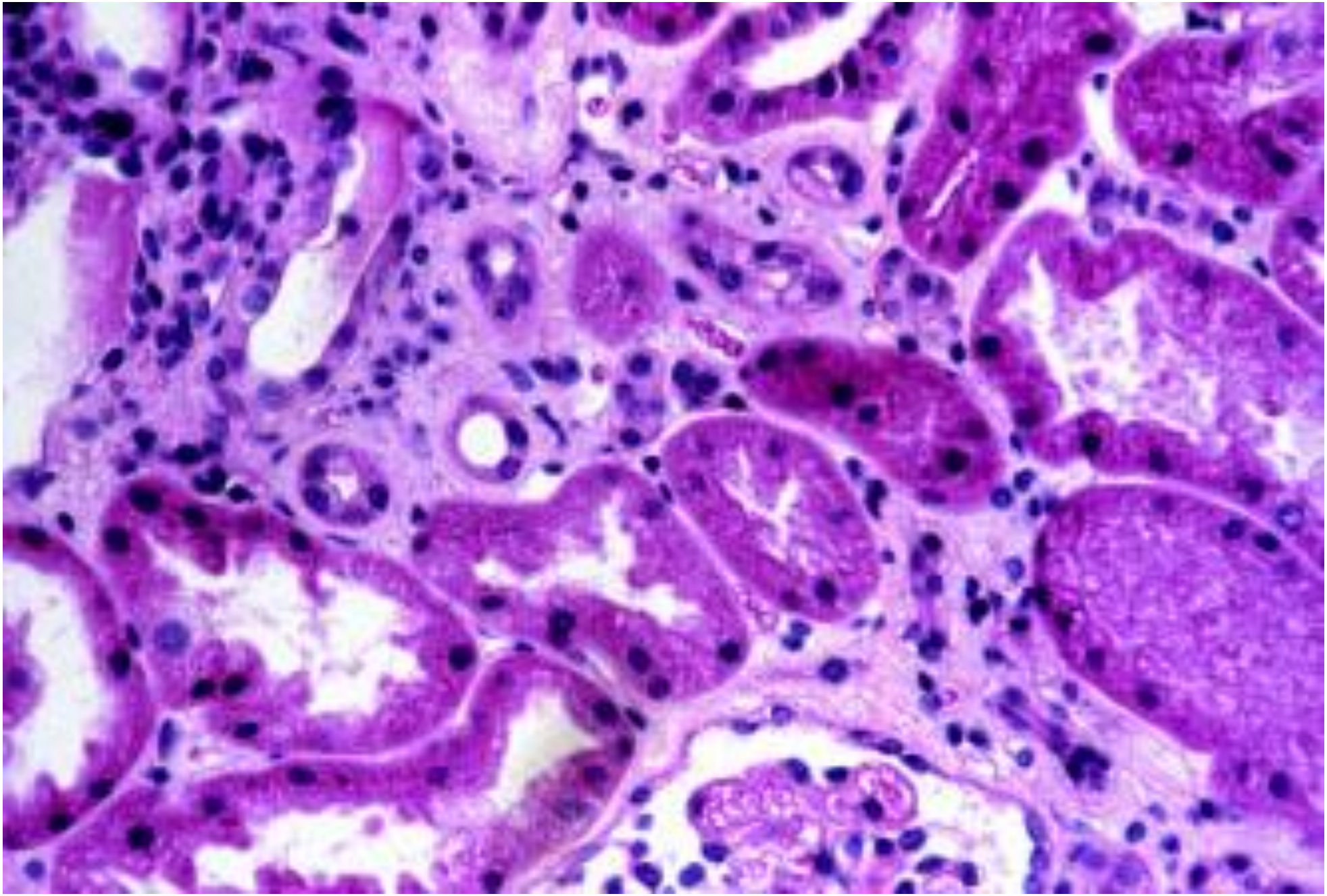

FIBROSE INTERSTICIAL RENAL:

Sistema Analisador de Imagens- KS 300

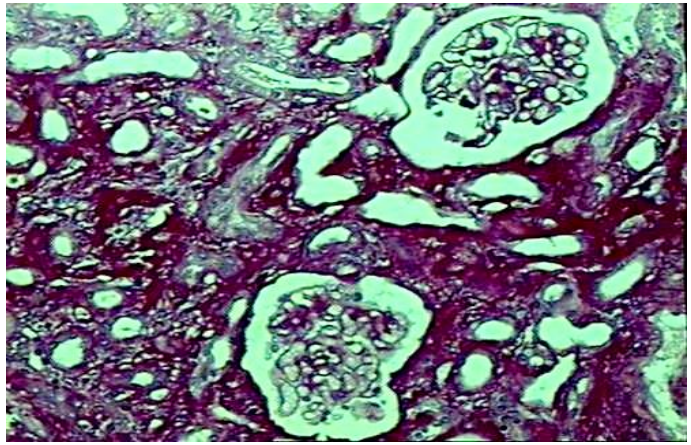

LUZ

POLARIZADA

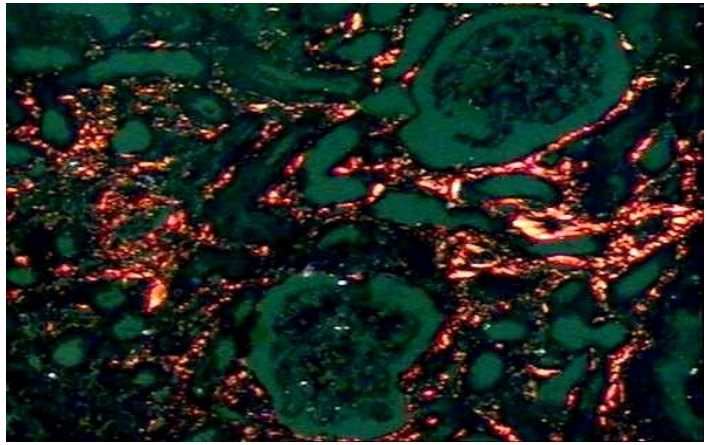

PICRO-SÍRIUS 600 X

50 campos representativos

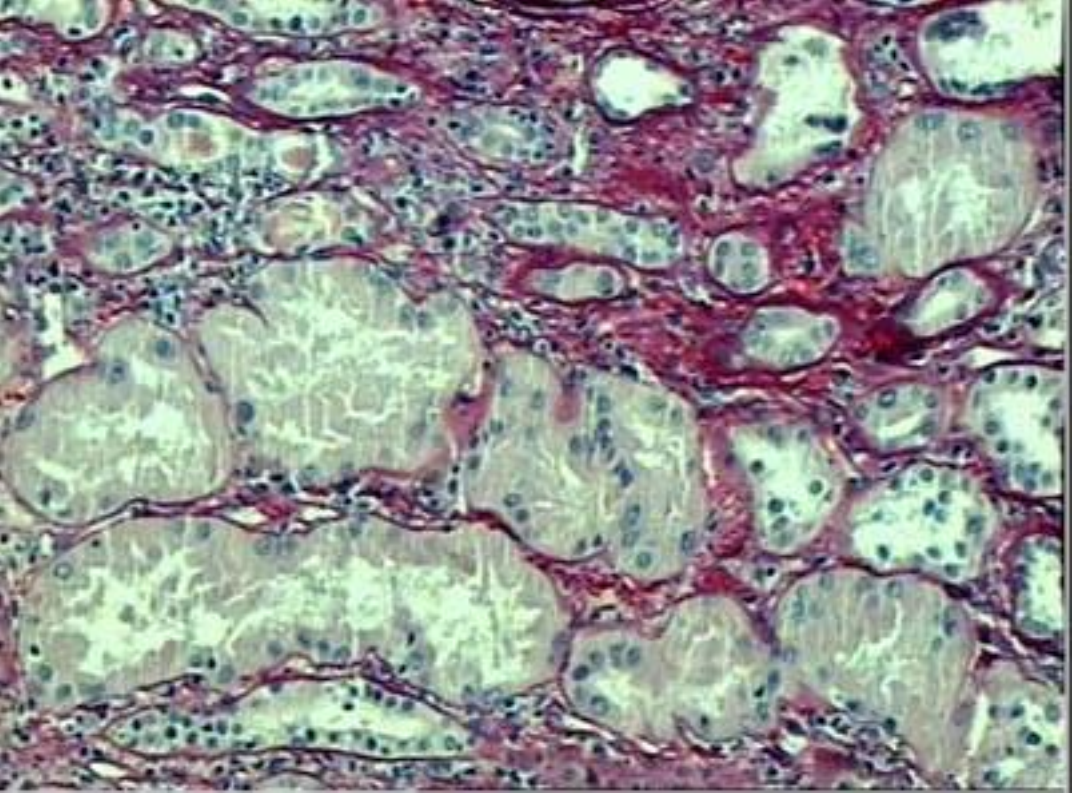

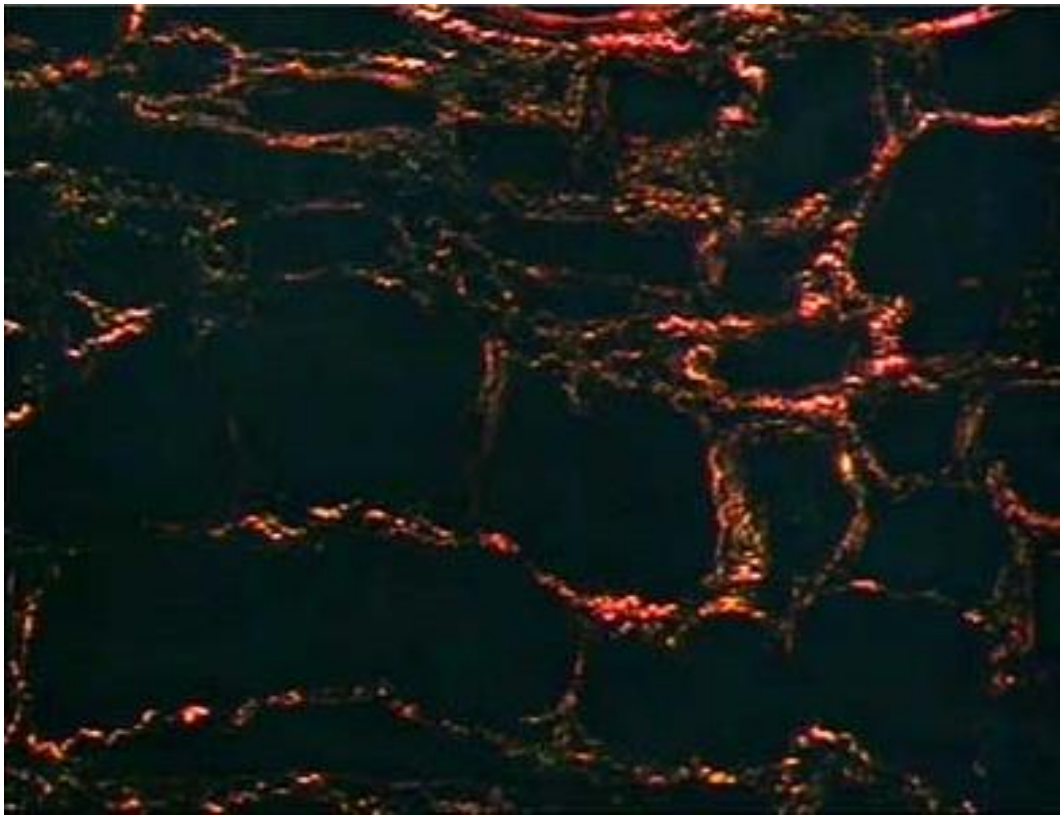

Picro-sírius, luz polarizada 320X

Table 2. Interstitial and vascular lesions of DN

Lesion	Criteria	Score
Interstitial lesions		
IFTA	No IFTA	0
	<25%	1
	25% to 50%	2
	>50%	3
interstitial inflammation	Absent	0
	Infiltration only in relation to IFTA	1
	Infiltration in areas without IFTA	2
Vascular lesions		
arteriolar hyalinosis	Absent	0
	At least one area of arteriolar hyalinosis	1
	More than one area of arteriolar hyalinosis	2
presence of large vessels	–	Yes/no
arteriosclerosis (score worst artery)	No intimal thickening	0
	Intimal thickening less than thickness of media	1
	Intimal thickening greater than thickness of media	2

Tervaert TWC et al, 2010

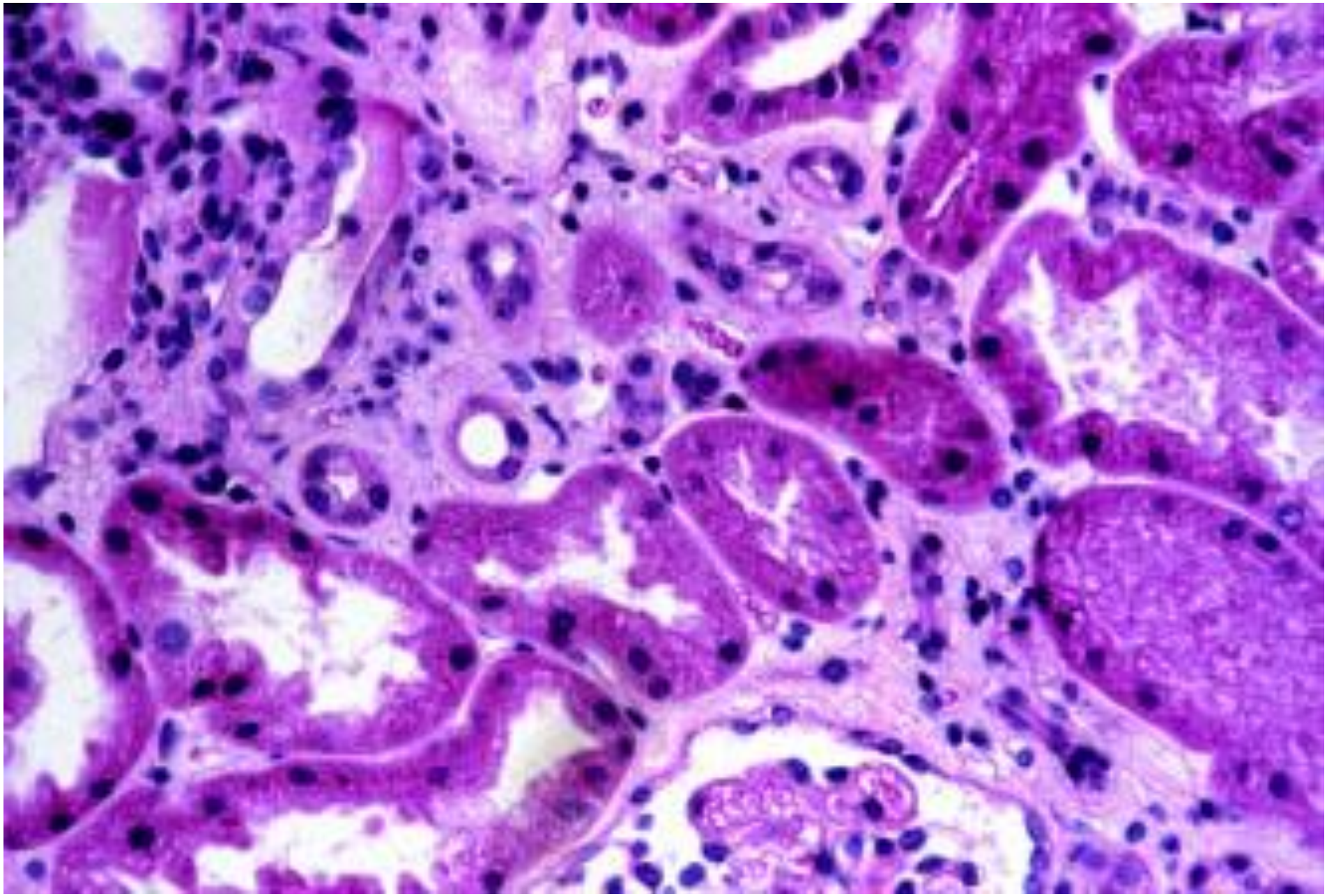

Table 2. Interstitial and vascular lesions of DN

Lesion	Criteria	Score
Interstitial lesions		
IFTA	No IFTA	0
	<25%	1
	25% to 50%	2
	>50%	3
interstitial inflammation	Absent	0
	Infiltration only in relation to IFTA	1
	Infiltration in areas without IFTA	2
Vascular lesions		
arteriolar hyalinosis	Absent	0
	At least one area of arteriolar hyalinosis	1
	More than one area of arteriolar hyalinosis	2
presence of large vessels	–	Yes/no
arteriosclerosis (score worst artery)	No intimal thickening	0
	Intimal thickening less than thickness of media	1
	Intimal thickening greater than thickness of media	2

Tervaert TWC et al, 2010

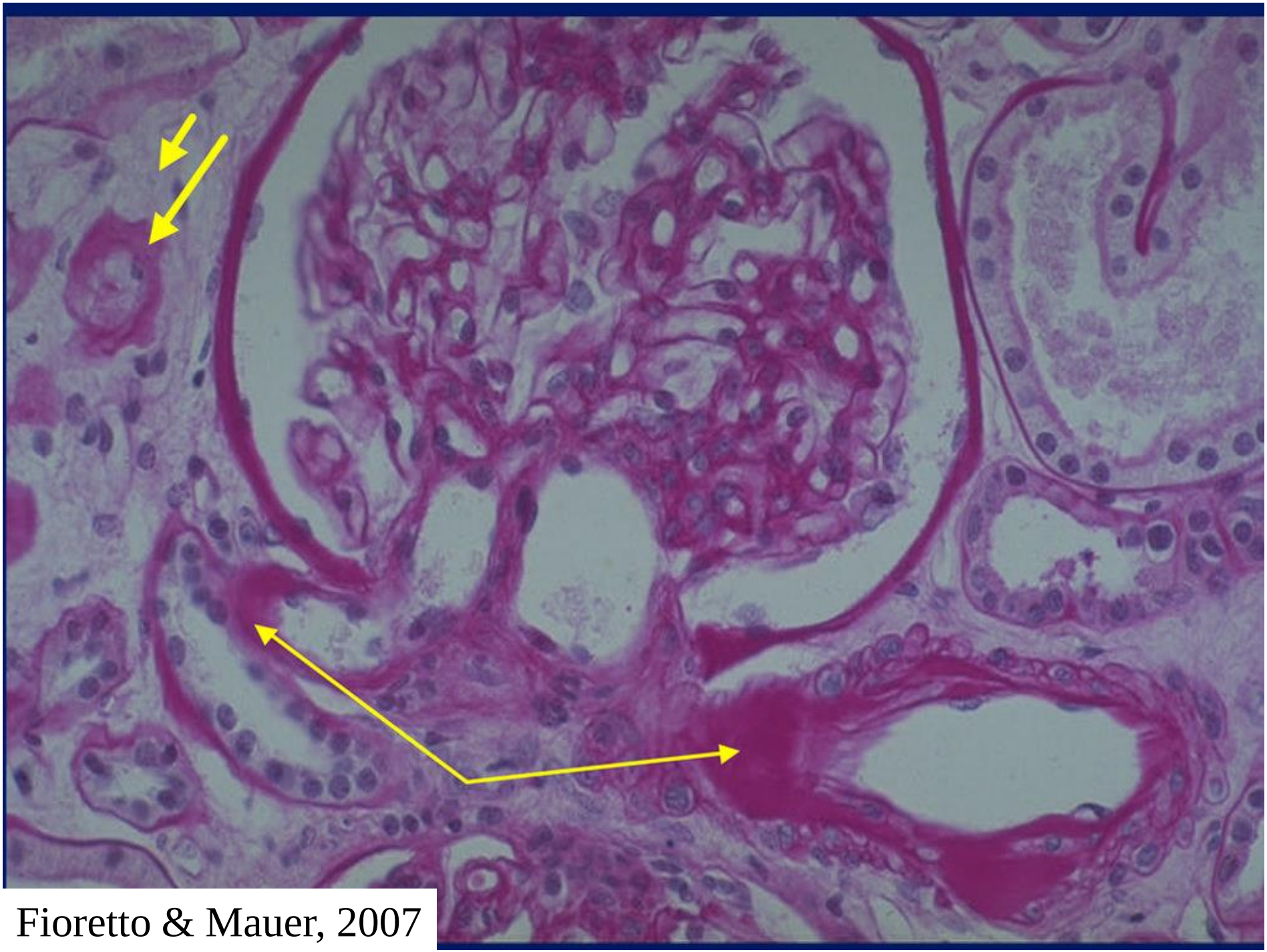

Fioretto & Mauer, 2007

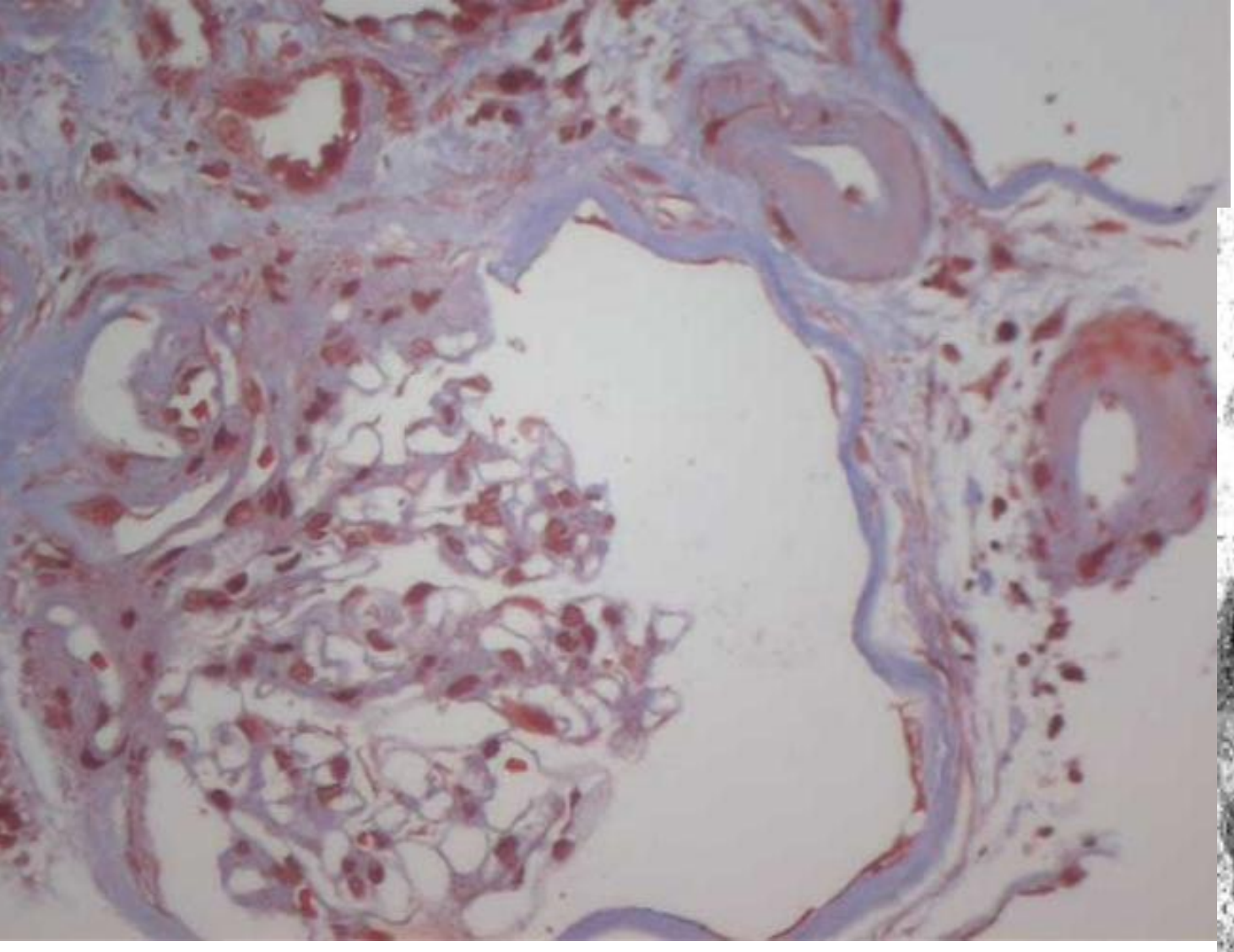

BR110317_TM, 20x2,0

“capsular drop”

- fortemente sugestivo de diabetes
- hialinose entre MB e epitélio da cápsula de Bowman
- prata negativo

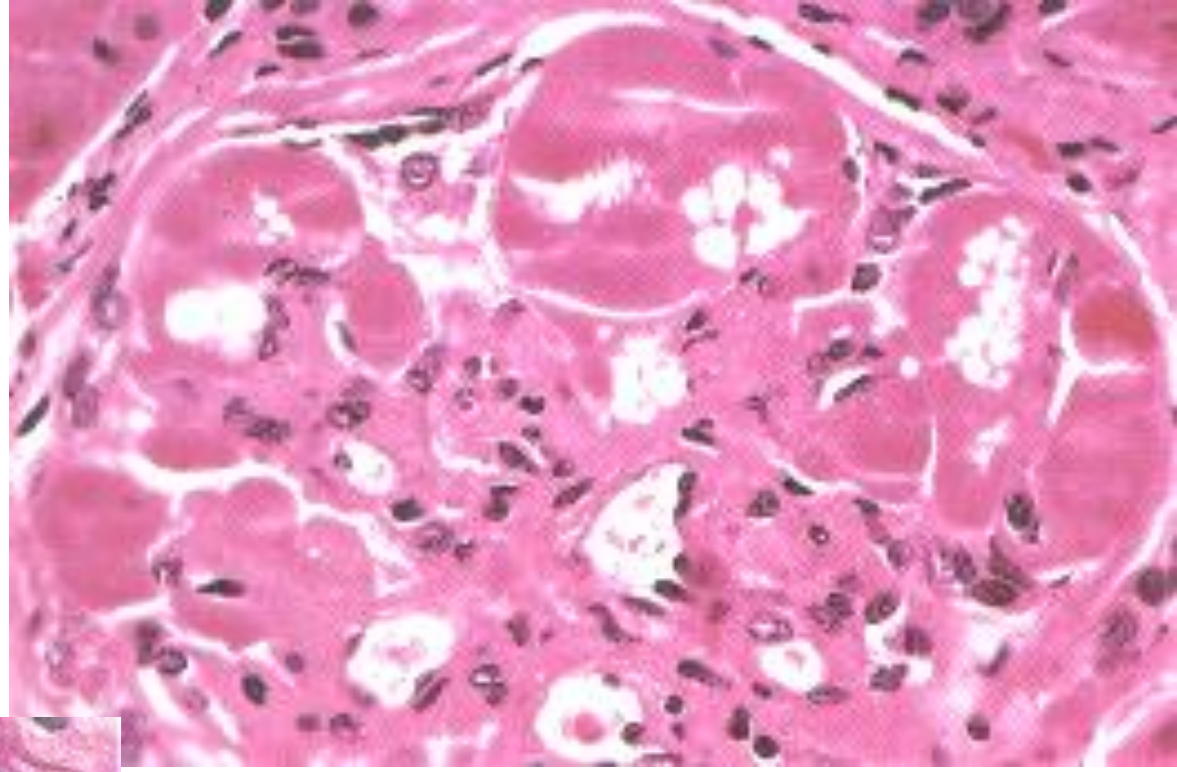

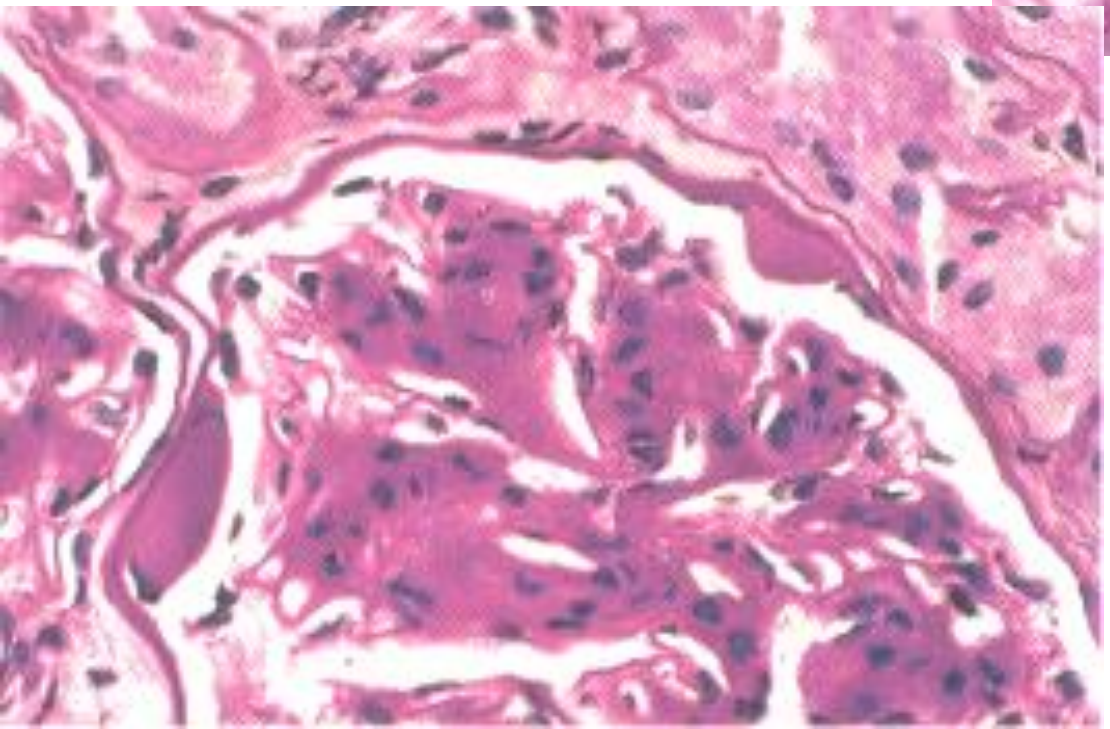

“fibrin cap”

- entre MBG e endotélio
- proteinas e lipideo

Table 2. Interstitial and vascular lesions of DN

Lesion	Criteria	Score
Interstitial lesions		
IFTA	No IFTA	0
	<25%	1
	25% to 50%	2
	>50%	3
interstitial inflammation	Absent	0
	Infiltration only in relation to IFTA	1
	Infiltration in areas without IFTA	2
Vascular lesions		
arteriolar hyalinosis	Absent	0
	At least one area of arteriolar hyalinosis	1
	More than one area of arteriolar hyalinosis	2
presence of large vessels	–	Yes/no
arteriosclerosis (score worst artery)	No intimal thickening	0
	Intimal thickening less than thickness of media	1
	Intimal thickening greater than thickness of media	2

Tervaert TWC et al, 2010

Artérias

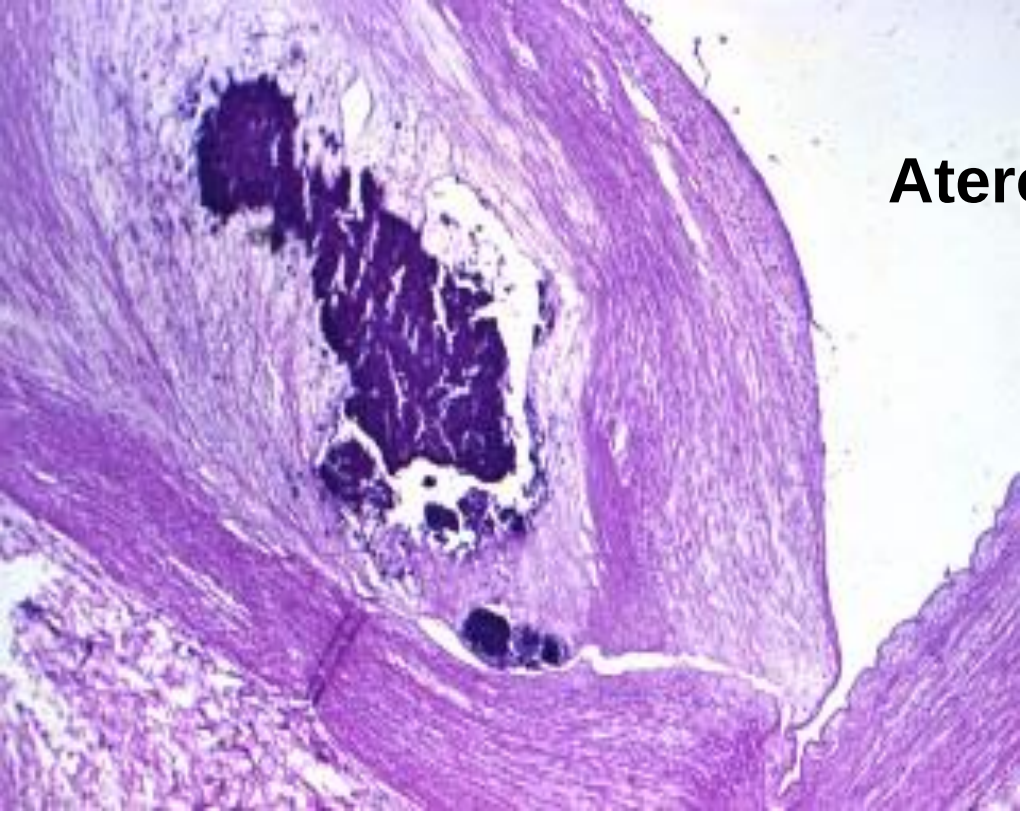

Aterosclerose

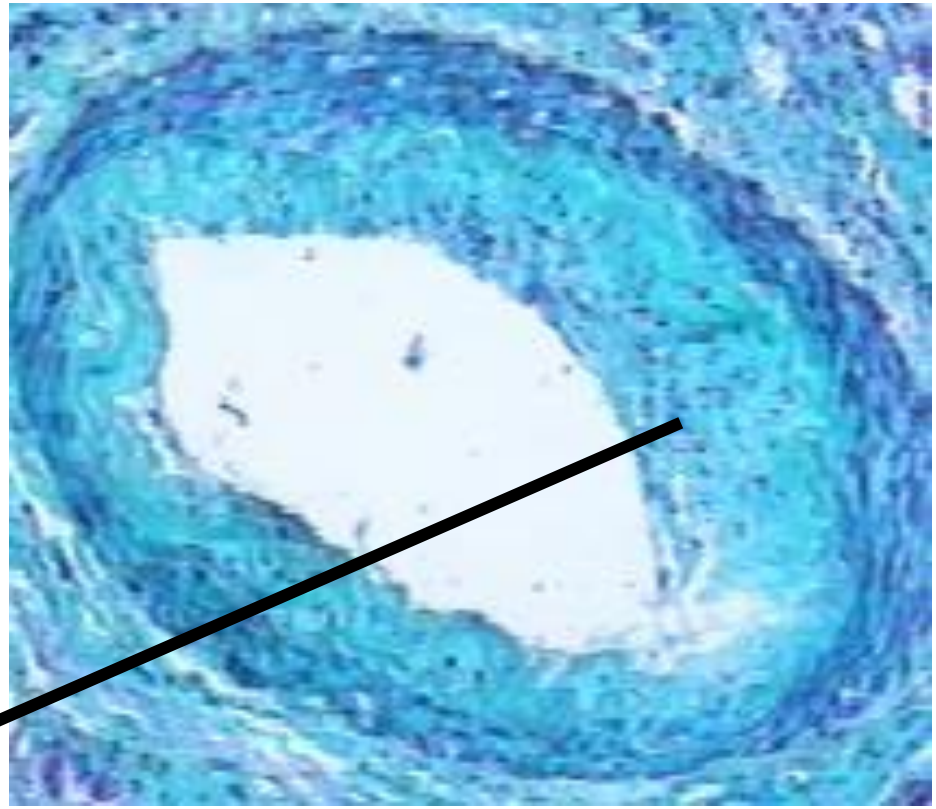

Espessamento Fibroelástico da íntima

Banco imagens Patge - UFTM

Tricrômico de Masson

IF

- Afastar outras entidades
- Doenças sobrepostas

ME

- Diagnóstico ND classe I
- Afastar outras entidades
- Doenças sobrepostas

BR130619
65 anos

20 DM + HAS
Insulino dependente

Prot: 1,4g/24h
1 semana: Snefritica
Creat: 2,3mg/dl
Era nl há 15 dias

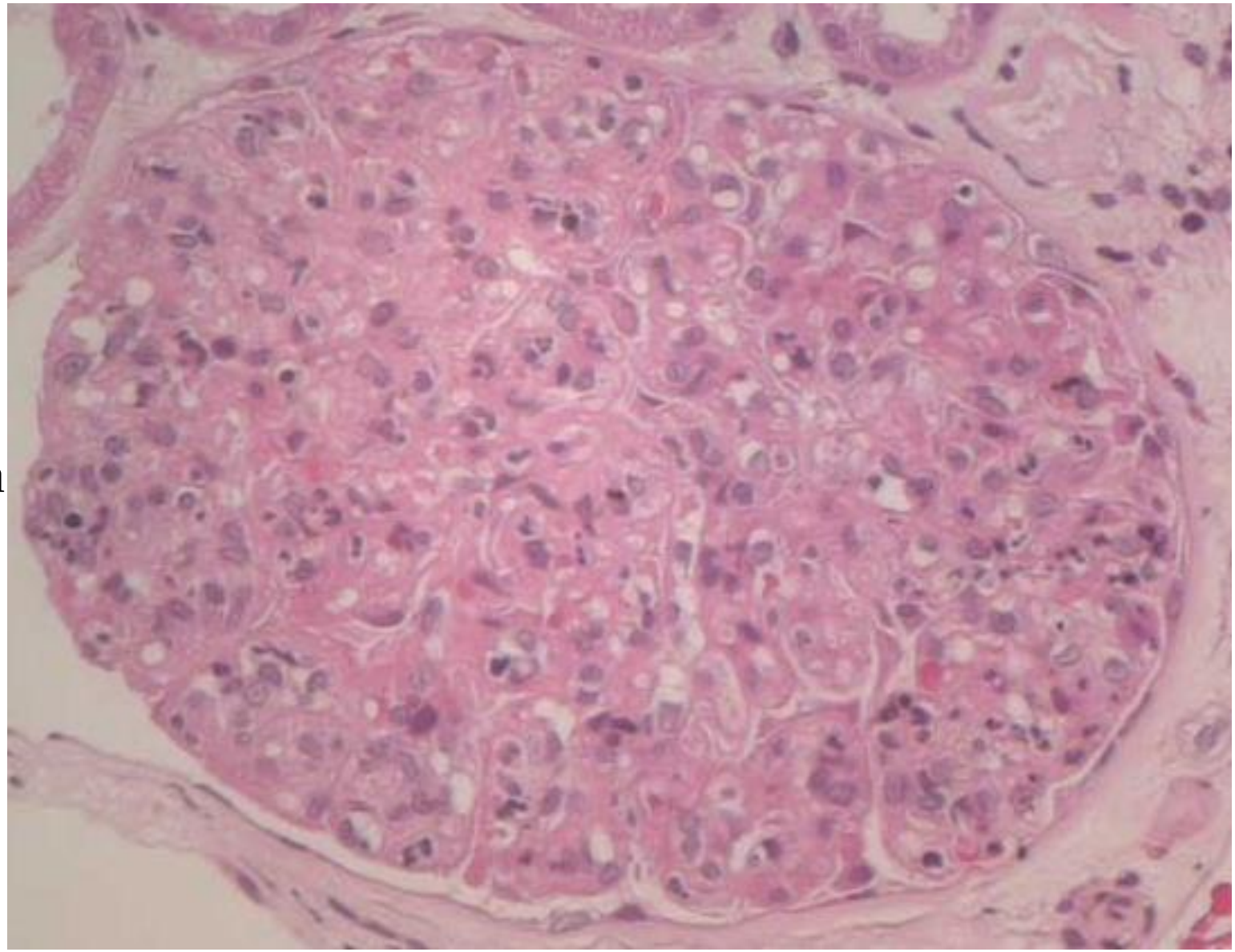

IF: C3

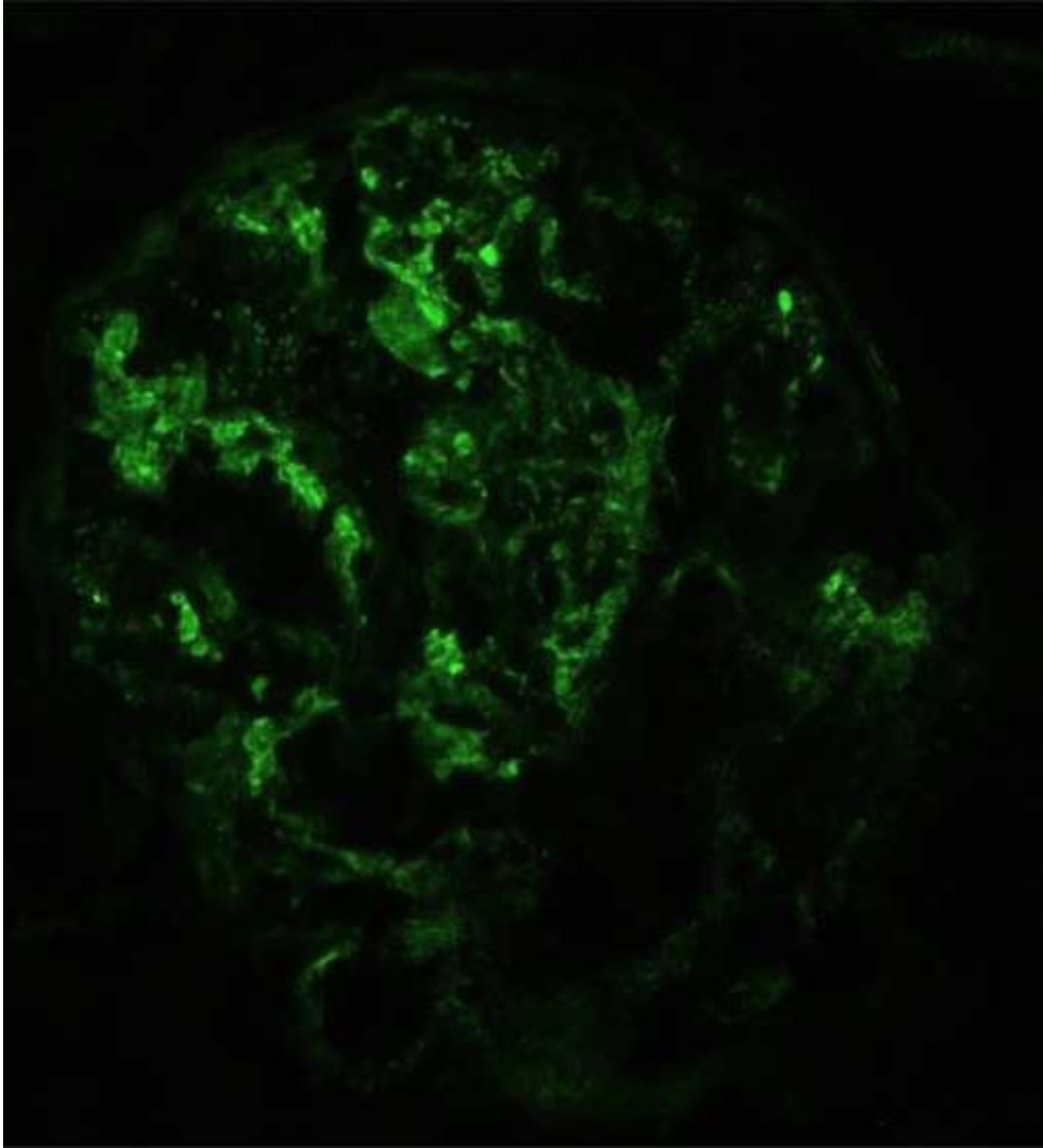

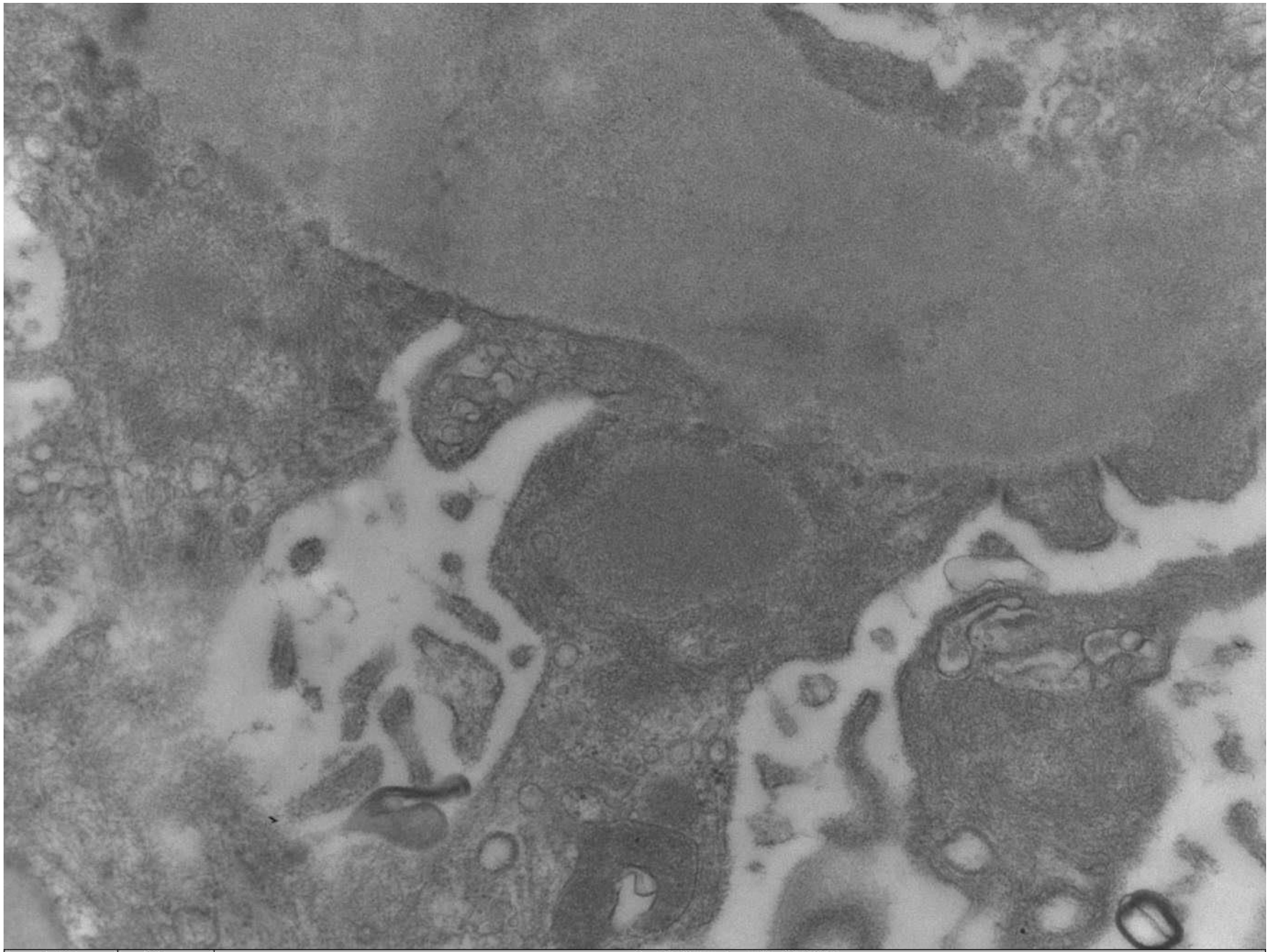

HV	Mag	Br130521_ME2668a
80000 kV	20000 x	1 µm

Glomerulonefrite Difusa Global Aguda - GNDA, provavelmente pós/per infecciosa

Nefropatia Diabética - Classe IV – Glomeruloesclerose Diabética avançada (>50% glomérulos esclerosados, segundo Tervaert et al., 2010), com 20/34 glomérulos esclerosados;

espessamento das membranas basais tubulares e de cápsula de Bowman e **arterioloesclerose hialina** acentuada.

Repercussões túbulo intersticiais moderadas a acentuadas (fibrose intersticial e atrofia tubular).

Biópsia renal percutânea

ME – glutaraldeido ou Karnovosky
+ vermelho de rutênio

IF

10 glomérulos

ML – Paraformaldeído

IF

- Afastar outras entidades
- Doenças sobrepostas

ME

- Diagnóstico ND classe I
- Afastar outras entidades
- Doenças sobrepostas

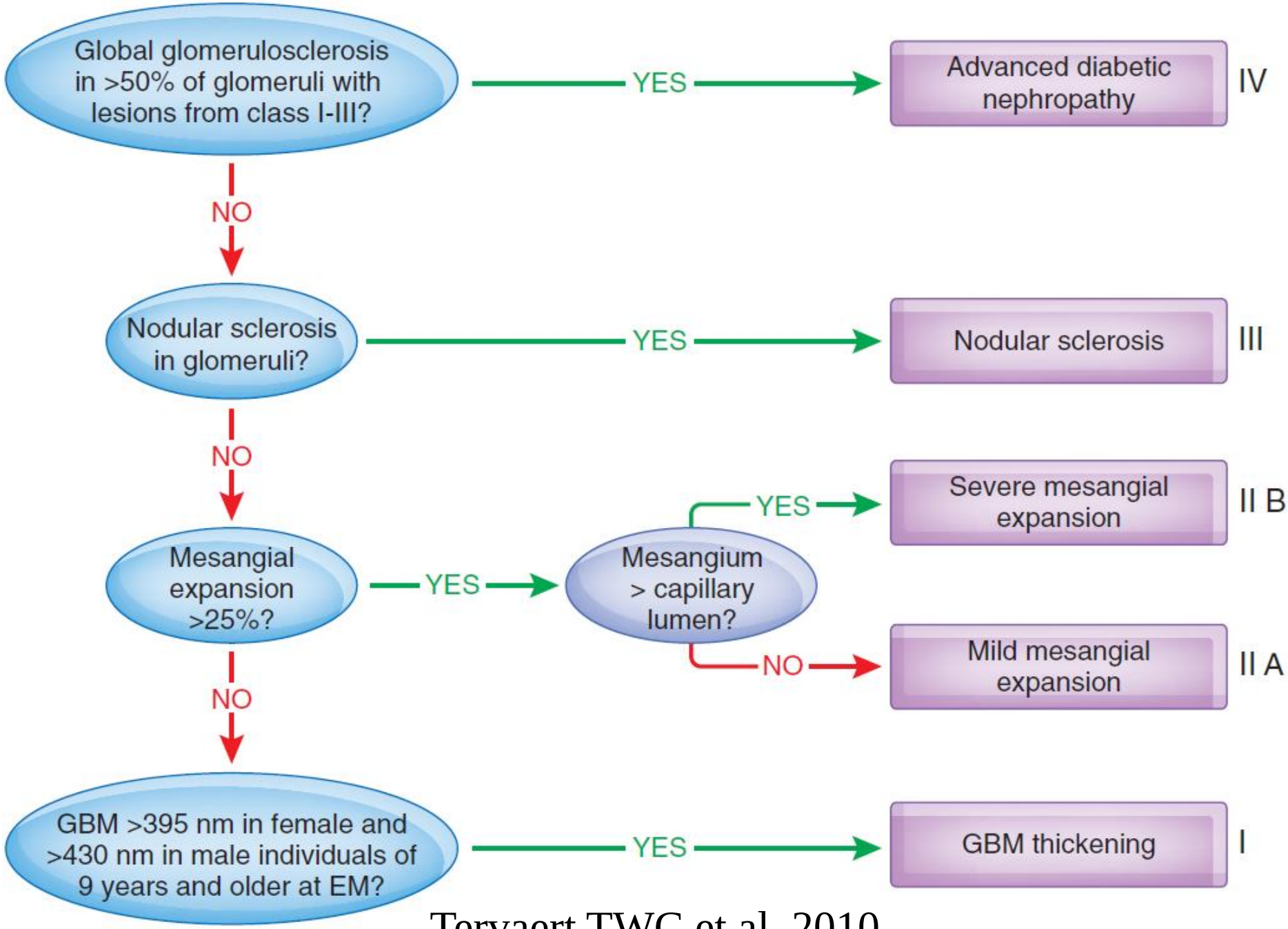

Tervaert TWC et al, 2010

Ministério da Educação
Universidade Federal do Triângulo Mineiro, Uberaba, MG
Disciplina de Patologia Geral

Nefropatia Diabética

Marlene Antônia dos Reis
mareispatologia@gmail.br